

Experience of Transfistula (TFARP) Repair for Congenital Recto-Vestibular Fistula

Humam S. Alkhaffaf¹

¹ Hawler Medical University/Medical college

Received: 8 December 2013 Accepted: 5 January 2014 Published: 15 January 2014

Abstract

Background: The objective of this study is to assess the feasibility of a primary transfistula anorectoplasty (TFARP) in congenital recto-vestibular fistula without a covering colostomy in the north of Iraq. **Patients and Methods:** Female patients having imperforate anus with congenital rectovestibular fistula presenting to pediatric surgical centres in the north of Iraq (Mosul & Erbil) between 1995 to 2011 were reviewed in a nonrandomized manner, after excluding those with pouch colon, rectovaginal fistula and patients with colostomy. All cases underwent one stage primary (TFARP) anorectoplasty at age between 1-30 months, after on table rectal irrigation with normal saline & povidone Iodine. They were kept nil by mouth until 24 hours postoperatively. Postoperative regular anal dilatation were commenced after 2 weeks of operation when needed. The results were evaluated for need of bowel preparation, duration of surgery, cosmetic appearance, commencement of feed and hospital stay, postoperative results. Patients were also followed up for assessment of continence and anal dilatation.

Index terms— anorectal malformation, vestibular fistula, primary transfistula anorectoplasty.

1 Experience of Transfistula (TFARP) Repair for

Congenital Recto-Vestibular Fistula Humam S. Alkhaffaf

Abstract-Background: The objective of this study is to assess the feasibility of a primary transfistula anorectoplasty (TFARP) in congenital recto-vestibular fistula without a covering colostomy in the north of Iraq.

Patients and Methods: Female patients having imperforate anus with congenital rectovestibular fistula presenting to pediatric surgical centres in the north of Iraq (Mosul & Erbil) between 1995 to 2011 were reviewed in a nonrandomized manner, after excluding those with pouch colon, rectovaginal fistula and patients with colostomy. All cases underwent one stage primary (TFARP) anorectoplasty at age between 1-30 months, after on table rectal irrigation with normal saline & povidone Iodine. They were kept nil by mouth until 24 hours postoperatively. Postoperative regular anal dilatation were commenced after 2 weeks of operation when needed. The results were evaluated for need of bowel preparation, duration of surgery, cosmetic appearance, commencement of feed and hospital stay, postoperative results. Patients were also followed up for assessment of continence and anal dilatation.

Results: A total of 73 patients with an age range of 1-30 months (median, 15.5 months) were studied after excluding one with pouch colon and another with rectovaginal fistula.

Operative time ranged from 60 to 80 min (median, 70 min). Bowel preparation was not done before operation. Oral feeding was started after 24h in all patients and average duration of hospital stay was 3 days. Parents of 8 cases (10.9%) were related, however in spite of that, a positive family history was found in only one case (1.3%). Follow-up ranged from (1 -14) years (median, 7.5 years). There were 2 wound infections. Wound dehiscence was noted in one case (1.4%); no recurrence of fistula was noted. At 3 months postoperative, most patients had 1 -3 stools per day with no episodes of soiling. Twelve (16.4%) patients had grade I-II constipation and

2 Introduction

It is reported that the majority of girls with imperforate anus will have a lesion of the low variety with a fistula to the perineum, fourchette or vestibule. Imperforate anus occurs in one of 5000 live births (1). According to the international classification of anorectal malformations, anteriorly placed anus includes anovestibular fistula, anoperineal fistula (low anomalies) and rectovestibular fistula (intermediate anomaly).

According to Pena's classification, these low anomalies are classified into perineal and vestibular fistula. Pena did not distinguish between rectovestibular and anovestibular fistula (2).

The close proximity of the ectopic anus with the vulva and the stenosed opening seen in large majority of cases necessitates some form of surgical correction. The anovestibular fistula is too far forward and too close to the vagina for a cut back operation (4). A variety of surgical procedures like posterior anal transposition, Mollard's operation, anterior or posterior sagittal anorectoplasty with or without a diverting colostomy have been done (5). Sigalet et al used a simplified Mollard's approach (PSARP) for repair of anorectal malformations which avoids skin flaps and constructs a shorter, more normal anal canal through a perineal approach via an anterior sagittal incision, but it was usually combined with a transverse suprapubic laparotomy (1). Dr. Willis Potts described Anal Transposition for vestibular fistula, Single stage repair for anorectal malformations has been advocated by a few studies with good results and concluded that single stage repair in neonates is safe with minimal complications (2,3,4).

We report our experience with 73 girls with vestibular anus including results of long term follow up, hospital stay with regard to quality of continence and cosmetic appearance.

3 II.

4 Patients and Methods

Seventy six female patients having congenital imperforate anus and anorectovestibular fistula presenting to our (Mosul + Erbil) pediatric surgical center were included in the study, in a nonrandomized manner. Between (Jan 1995 to September 2011). All cases were done by one consultant surgeon. Mosul & Erbil are two cities of five millions populations sum in north of Iraq. All cases had a well formed perineum & gluteal region. A contrast enema was performed in the presence of constipation or straining at stools despite an adequate size opening, to rule out pouch colon. Three patients, one baby with pouch colon and another with Rectovaginal fistula were excluded from the study in addition patient with colostomy. All 73 patients underwent ultrasonography of kidneys, ureters, and bladder as outpatients. An echocardiography was also performed where indicated. All patients were screened by sacral x-rays for presacral mass and sacral ratios. In addition checking was done for associated spinal cord anomalies. Patients were admitted a day before operation when samples for hemogram (Full Blood Count), serum electrolytes, and blood urea/serum creatinine estimation were taken. The child was allowed clear fluids by mouth until 4 hours before the surgery. A foley's catheter was placed through the urethra under G/A. Rectal fistula was washed with 20-25 cc /kg warm normal saline + povidon Iodine in a concentration of 1:10 for 10min while the patient was anaesthetized before commencement of surgery (on table preparation). We usually use a nasogastric tube, fixed by approximating the gluteal region by adhesive plasters rather than using a ballooned catheter. A broad spectrum antibiotic (Claforan /or Ceftriaxone) was given at commencement of G/A. All patients were operated on under general anesthesia using an TFARP (modified anorectoplasty) approach in the lithotomy position. Electrical stimulation & hyperpigmentation were used to locate the anal site, and an inverted U shaped skin incision was made at the anal site before fistula separation, then a plane was dissected between the muscle complex going anteriorly (fig1). Fine silk traction a round the fistula and freed after an elliptical transverse incision and sufficient length rectum was dissected and the vagina was separated using loop magnification (Fig. 2). a clamp passed after making a tunnel through the anal sphincter and the released anorectum was pulled through to the proposed anal site (Fig. ??). The rectum was fixed to the muscle by multiple fine stitches (6/0 vicryl). The fistulous region was excised and a proper anoplasty was done, and the site of the primary fistula was closed in layers after repairing the perineal body. Saline injection with adrenaline was used in all cases for dissection to minimize the blood loss. No blood was given during operation in all patients. Patients were evaluated for the duration of the operation, commencement of the oral feed, hospital stay and the postoperative results. Patients were kept nil by mouth for the following 24 hours to delay bowel motion. They were kept on intravenous fluids and similar parenteral broad spectrum antibiotics during this period. The urinary catheter was removed after 24 hours postoperative. Mothers were advised to keep the perineal area clean with diluted povidine iodine and normal saline. Anal dilatation was done after 2 weeks of operation when required. All patients were regularly followed up, twice in a month for the first 3 months; monthly for the next 6 months; every 3 months for the next year; and then yearly. They were followed for a minimum period of at least three years. The perineal area was inspected for any excoriation, wound infection, wound dehiscence as well as anal stenosis, retraction, mucosal prolapse or recurrence of fistula. They were assessed for constipation and voluntary bowel movements.

5 Results

A total of seventy three patients were included in this study after excluding two patients. Mean age of presentation was 45 days (range, 1-90 days). Sixty patients were term & 13 were preterm. Fifteen of them were delivered by C/S while the remaining had a normal vaginal delivery. Fifty percent of mothers were in the age range 25-29 years and 50% of them were between para 2-4. Although 40% of parents were related, family history was positive in only 1 case (1.3%). Early diagnosis was done for all cases in the neonatal period, except for 3 patients who were 3 months old at diagnosis. All patients had RVF malformation with the distance of vagina from anus between 2-5 mm. Forty eight cases (65.7%) were free of associated anomalies, 25 cases (34.2%) had associated anomalies, 14 (19.1%) of them had more than one associated anomaly. Seven (9.5%) had Congenital Heart Disease (4 VSD, 2 ASD, 1 TOF), 11 (15%) had associated renal anomalies (5 VUR, 2 Rt Renal agenesis, 1 Horse shoe kidney, 1 Rt single kidney, 2 unilateral pelvic kidney), 1 (1.3%) with 1st branchial fistula, 3 (4.1%) with polydactyly, and three (4.1%) were associated with Down's syndrome (Table 1). 48 (65.7%) patients were operated on between 1-3 months, while others were done later either because of associated anomalies or their parents had refused early surgery, (Table 2) Median age of operation was 7 months.

No antibiotics used preoperatively, only prophylactic on table AB "Claforan". All patients were fasting apart from clear fluids 4-6 hours preoperatively. 12 cases had stenosis preoperatively and underwent preoperative dilation. Bleeding during surgery was minimal by the application of diluted adrenaline. Two cases had mild injury to the posterior vaginal wall, all were sutured immediately. Oral feeding was started 24 h after surgery. Patients were passing stool 4-6 times per day after operation. Range hospital stay was 2-4 days. At follow-up, patients were healthy and passed stool 2-3 times a day. All patients started to pass bowel motions 2-4 days postoperatively. Five patients had anal stenosis. Minimal constipation was observed in 18 (24.6%) patients and was managed by regular dilatation and laxatives. Superficial wound infection was seen in 5 patients (6.84%), of which, healed by local dressing, toilet and antibiotics, whereas in 2 cases (2.73%) disruption & dehiscence of the wound developed, one of them was on aspirin after cardiac surgery. Fortunately the sphincter was intact, & secondary suturing was done for them after toileting without a protective colostomy (Table 3). Three patients were seen to have mild mucosal prolapse, managed by excision later on. Follow up was between one to fourteen years with median period of 7 years.

6 Discussion

This study was conducted in single center (Erbil) from two cities in north of Iraq for 15 years from (1995 to 2011). It may reflect the high incidence of anorectal anomalies of recto vestibular and anovestibular fistulas among female in regard to rectovaginal and cloaca. In this study the rectovestibular were more common in number (n=58) 79.45% than anovestibular (n=15) 20.54%. which is similar to the study of pena (1) and J shaheed (2).

In our study age distribution was between one and thirty months, among them 48 cases (65.75%) between 0-3 months, 17 (23.2%) between 4-6 months, 5 (6.8%) at 7 months, 2 (2.7%) at 14 months, 1 (1.3%) at 30 months. This high number of early presentation in the first three months most likely due to absence of normal anal opening or difficulty in passing motion or early detection of the anomaly at maternity hospital which is seen similar to J shaheed (2) and Okada (3) (5). and JS kamal (6).

From the experience of Menon et al., the ideal time for primary Anorectoplasty appears to be the age of 3 months because the baby is still on milk feeds at 3 months, stools are soft, and usually there are no problems with defecation. The risks of anesthesia are reduced at 3 months as compared with the newborn period. There is also enough time to fully assess other anomalies, especially cardiac and renal complications (7). In our study most cases 48 (65.75%) were between 1-3 months age and they were (88.95%) in the first 1-6 months of age. comparing with J shaheed they were 58% in first month and 83.7% below six months which are nearly the same, while they were 45% in the same age in Saber M. Waheeb (8).

Regarding bowel preparation in our study we found that preoperative bowel irrigation with povidine iodine and normal saline under G/A was easy and safe, no soiling during surgery, there were reduced number of wound sepsis, and admission period. We have seen 5 patients with superficial wound infection (6.84%). 2 wound disruption (2.73%). while it was 2 cases (10%) wound infection and 1 (5%) wound disruption in J Shaheed Suhrawardy (2), and all vestibular anus healed completely with no infection (100%) in Akshay et al (4).

The trans fistula anal transposition preserves an intact perineal skin bridge which eliminates the risk of wound problems; also the levator muscle is identified but not divided. (shi Sh.9) We believe that in TFARP normal skin bridge between the neo-anus and the repaired site of the fistula limits the risk of wound dehiscence, as we have only 2 (2.73%) cases of wound disruption one of them was on aspirin (cardiac surgery), and also a better cosmetic result due to lack of an incision and scar. The rectum can be dissected easily, placed properly within the muscle complex (2).

The perineal body and posterior fourchette are closed precisely from within outwards (9). TFARP is considered more acceptable with regards to surgical outcome and aesthetic appearance of perineum as there is no visible scar mark in the perineum and strength of perineum is good as there is no interference of pelvic diaphragm and Reconstruction of perineal body with apposition vestibular and perineal wound was performed (9).

Regarding posterior vaginal injury, In our series 2 (2.73%) patients out of 73 had posterior vaginal wall injury during dissection which were repaired immediately by 6/0 vicryl without postoperative complication. while in Jshaheed series there were 4 (20%) vaginal wall injury (2). and it was only one case in Akshay et al (4).

operation time was between 45minutes and maximum time was 75minutes, mean operation time (60min). while the mean time was (76.5min) in J shaheed (2). and was (68min) in upadhyaya (10). Pratap A et al reported mean operating time 85 min (11). Mean hospital stay in our series was 3days while in J shaheed was 6.95days, and it was 4.4days in upadhyaya (10). Akshay et al was found 5 days mean hospital stay. Pratap A et al mean hospital stay was 5 days (11).

Commencement of oral fluid feeding was started 24h postoperative in our series, which is the same as in upadhyaya (10).

At the time of discharge all parents were told to report for planned time of follow up and anal dilatation if needed after 2weeks. we reported 5 cases (6.84%) of anal stenosis which were put on schedule of dilatation first at hospital then at home by their parents according to penia dilatation schedule. while upadhyaya series were 2cases (5%) with anal stenosis which needed dilatation, nearly similar to our series (10). While J shaheed reported all patients were put on anal dilatation schedule. 2. Pratap a et al reported moderate anal stenosis developed in 1 patient and was treated successfully by anal dilatations using Hegar dilators (11).

Follow up was between one to fourteen years with median period of 7years. Upadhyaya median followup was 3y (10), while Menos follow up was between 7m-8y (6). Functional outcome were evaluated. Minimal constipation (G1-2) was observed in 12 (16.4%) patients and was managed by laxatives, Upadhyaya reported 6 cases (15%) with constipation (10). Ibrahim et al reported 3 (12%) cases of constipation (12). Henien reported post operative functional constipation in 47% of patients with anteriorly placed anus and 50% in cases of vestibular fistula (13). Yeung and Kiely reported intractable constipation in 28% of their patients (14).

The need for a diverting colostomy in babies with vestibular fistula is debatable. Pena recommended a colostomy in all babies with vestibular fistula, because it is a defect that has a good functional prognosis and perineal wound complications after PSARP would compromise the outcome. The diverting colostomy also prevents dilatation of the rectum occurring prior to the definitive procedure. A dilated rectal pouch might affect the functional outcome after anorectoplasty (15). In all of our cases no colostomy was done, J Shahees (2) and upadhyaya (10) also had reported no colostomy in their series. Besides the disadvantages of the three stages procedure and the costs involved, repeated hospital admissions, colostomy in anorectal anomalies is associated with frequent and sometimes severe complications (patwardhan) (16). effectively performed without a covering colostomy with good cosmetic appearance and good anal continence, less morbidity, provided fecal contamination of the wound can be kept to the minimum in the first postoperative week. ¹



1

Figure 1: Fig. 1 :

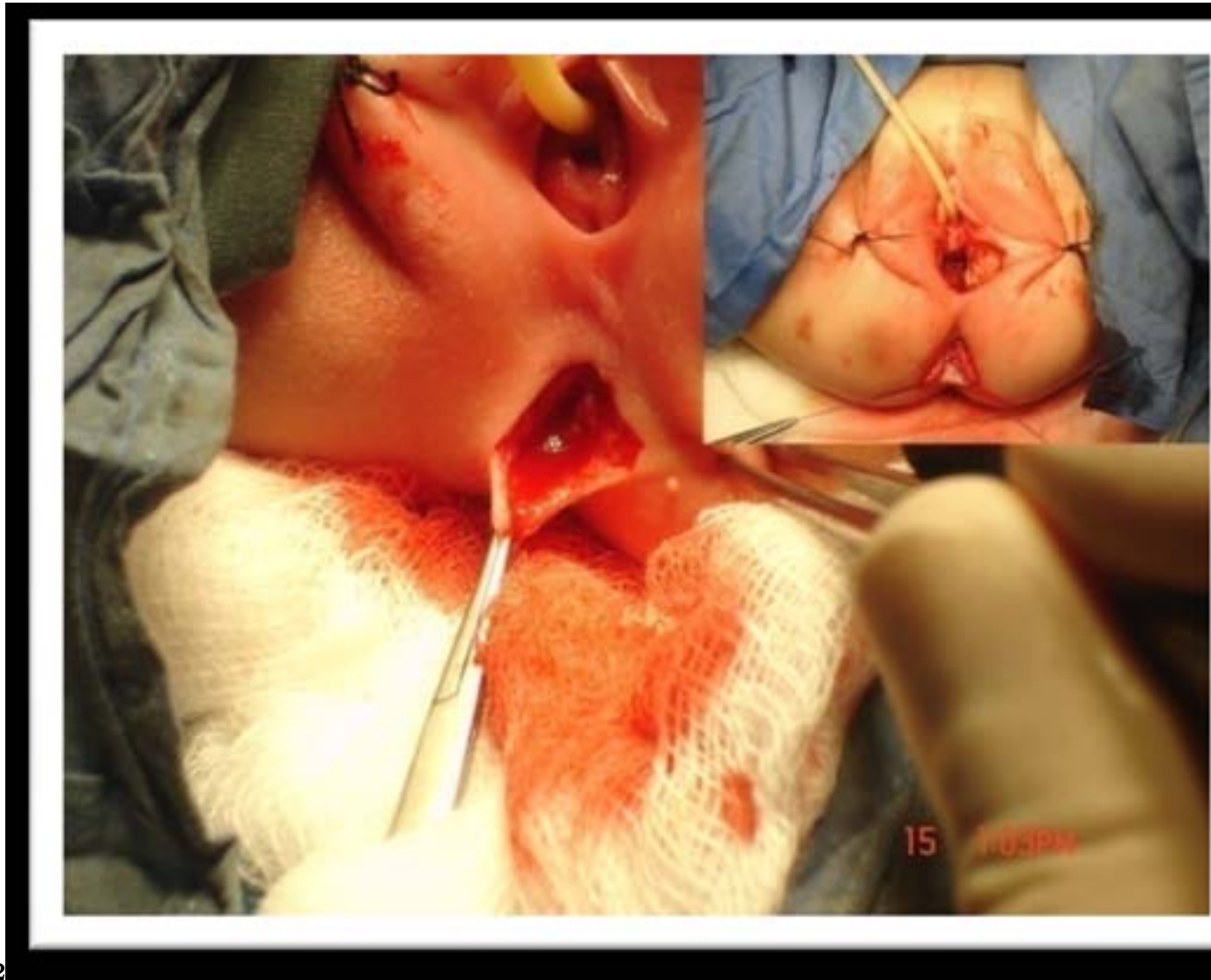


Figure 2: Fig. 2 :

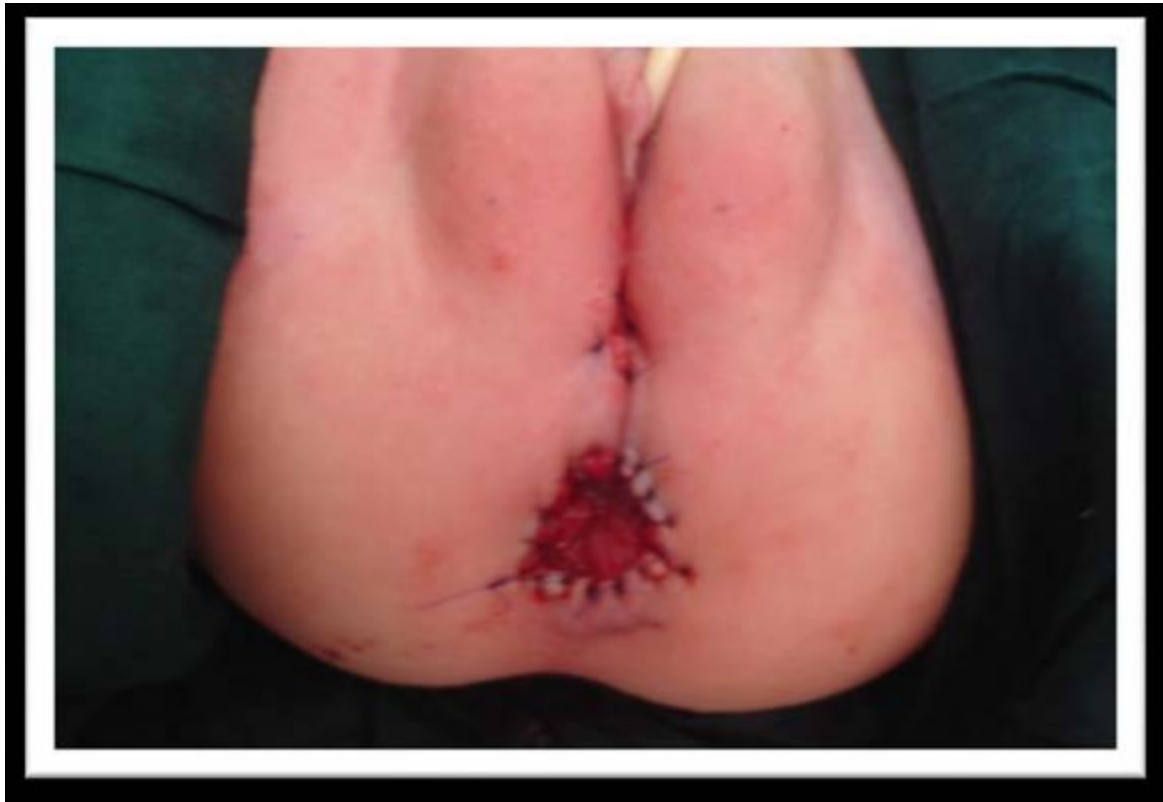


Figure 3: I

1

Figure 4: Table 1 :

2

Figure 5: Table 2 :

3

Complications & Follow-Up in the Study Group
IV.

Figure 6: Table 3 :

191 [World J Surg (2007)] , *World J Surg* 2007 Sep. 31 (9) p. .

192 [Pena ()] 'Advances in the management of ano-rectal malformations'. Hong Pena . *Am J Surg* 2000. 180 p. .

193 [Kamal] *Anal transposition (trans-sphincteric anorectoplasty) for recto-vestibular fistula-Saudi Journal for Health*
194 *Sciences*, Kamal . p. 2012. (org)

195 [Pena ()] *Anorectal anomalies'in Newborn surgery*, A Pena . 2003. Puri, Arnold, London. p. . (2nd edn)

196 [Pena et al. ()] 'Anorectal Malformations'. A Pena , M A Levitt , J L Grosfield , O' Neil , J A Fonkalsrud , E
197 W Coran , AG . *Pediatric Surgery. 6 th*, 2006. Mosby Elsevier. p. .

198 [Okada et al. ()] 'Anterior Saittal Anorectoplasty for Rectovestibular and Anovestibular fistula'. A Okada , K
199 Shinkichi , K Imura , M Fukuzawa , A Kubota , M Yagi , T Azuma , H Tsuji . *J Pediatr Surg* 1992. (1) p. .

200 [Patwardhan et al. ()] 'Colostomy for anorectal anomalies:high incidence of complications'. Patwardhan , E M
201 Kiely , D P Drake . *J Pediatr Surg* 2001. 36 p. .

202 [Yeung and Kiely ()] 'Low anorectal anomalies:a critical appraisa'. C K Yeung , E M Kiely . *Pediatr Surg Int*
203 1991. 6 p. .

204 [Akshay et al. ()] 'One stage correction of Rectovestibular fistula by transistula anorectoplasty'. P Akshay , R
205 P Yadav , V C Shekhar , A Singh , R Sen . *J, World surg vol* 2007. 31 (9) p. .

206 [Pratap et al.] *One-stage correction of recto-vestibular fistula by trans-fistula anorectoplasty (TFARP)*, A Pratap
207 , R P Yadav , V C Shakya , C S Agrawal , S N Singh , R Sen .

208 [Shi ()] 'Perineal skin bridge and levator muscle preservation in neutral sagittal anorectoplasty (NSARP) for
209 vestibular fistula'. S D Shi . *Pediatr Surg Int* 2005. 21 p. .

210 [Menon ()] 'Primary anorectoplasty in females with common Anorectal malformations without colostomy'. P
211 Menon . *Journal of Pediatric Surgery* 2007. 42 p. .

212 [Ibrahim and Korany (2007)] 'Samir A Ammar One Stage Posterior Anal Transposition for low and Intermediate
213 Aanorectal Anomalies in Females'. Ibrahim Ali Ibrahim , Mohamd Korany . *Annals of Pediatric Surgery* April
214 2007. 3 (2) p. .

215 [Vd Upadhyaya et al. ()] 'Single-stage repair for rectovestibular fistula without opening the fourchette'. Vd
216 Upadhyaya , Gangopadhyay , Pandey? . *Journal of pediatric ?* 2008. Elsevier.

217 [The Anterior Sagittal Anorectoplasty Technique (ASARP) for Treatment of Recto-Vestibular Fistulae and Vestibular Anus in ch
218 *The Anterior Sagittal Anorectoplasty Technique (ASARP) for Treatment of Recto-Vestibular Fistulae and*
219 *Vestibular Anus in children and Neonates* Saber M. Waheeb, October 2005. 1 p. .

220 [Heinen ()] 'The surgical treatment of low anal defects and vestibular fistulas'. F L Heinen . *Semin Pediatr Surg*
221 1997. 6 p. .

222 [Transistula Anorectoplasty (TFARP): Better Surgical Technique for the Management of Vestibular Fistula (2012)]
223 *Transistula Anorectoplasty (TFARP): Better Surgical Technique for the Management of Vestibular Fistula*,
224 June 2012. 4.