



GLOBAL JOURNAL OF MEDICAL RESEARCH: I  
SURGERIES AND CARDIOVASCULAR SYSTEM  
Volume 14 Issue 5 Version 1.0 Year 2014  
Type: Double Blind Peer Reviewed International Research Journal  
Publisher: Global Journals Inc. (USA)  
Online ISSN: 2249-4618 & Print ISSN: 0975-5888

## Preliminary Seton Before Fistulectomy: A Single Institute Experience in Treating Fistula in Ano; 1 Year Follow up Results

By Labib Al-Ozaibi, Wessam Hazim, Ali Al-Ani, Alya Al-Mazrouei, Faisal Al-Badri  
& Ahmed Al-Jaziri

*Dubai Health Authority- Rashid Hospital, United Arab Emirates*

**Abstract- Aim:** To analyze the results of treating fistula-in-ano using a preliminary Seton followed by fistulectomy and sphincter repair 2-4 months later.

**Method:** This is a retrospective study of 56 patients with transsphincteric and complex anal fistulas, managed preliminary with loose Seton followed by fistulectomy and sphincter repair 2-4 months later between March 2011 and March 2013. Patients were seen at the clinic 1 week, 3 months and 1 year after the surgery. Patients were observed for complications and recurrence and incontinence was noted according to Cleveland Clinic score.

**Result:** Twenty-five (45%) of the fistulas were high or complex. Twenty-nine (51.7%) of the patients had a history of previous surgery. Forty-nine (88%) of the cases were done as a day case surgeries. The Seton was kept in situ for 2-5 months (average 2.6 months).

**Keywords:** anal fistula; seton; fistulectomy.

**GJMR-I Classification:** NLMC Code: WI 480



*Strictly as per the compliance and regulations of:*



# Preliminary Seton Before Fistulectomy: A Single Institute Experience in Treating Fistula in Ano; 1 Year Follow up Results

Labib Al-Ozaibi <sup>α</sup>, Wessam Hazim <sup>σ</sup>, Ali Al-Ani <sup>ρ</sup>, Alya Al-Mazrouei <sup>ω</sup>, Faisal Al-Badri <sup>¥</sup> & Ahmed Al-Jaziri <sup>§</sup>

**Abstract- Aim:** To analyze the results of treating fistula-in-ano using a preliminary Seton followed by fistulectomy and sphincter repair 2-4 months later.

**Method:** This is a retrospective study of 56 patients with transsphincteric and complex anal fistulas, managed preliminary with loose Seton followed by fistulectomy and sphincter repair 2-4 months later between March 2011 and March 2013. Patients were seen at the clinic 1 week, 3 months and 1 year after the surgery. Patients were observed for complications and recurrence and incontinence was noted according to Cleveland Clinic score.

**Result:** Twenty-five (45%) of the fistulas were high or complex. Twenty-nine (51.7%) of the patients had a history of previous surgery. Forty-nine (88%) of the cases were done as a day case surgeries. The Seton was kept in situ for 2-5 months (average 2.6 months). Complete healing was achieved within 3.7 weeks on average (2-8 weeks). The mean follow up was 20.5 months (12-36 months). Two patients had temporary flatus incontinence which had both resolved over a period of 2-3 months. Recurrence happened in two (3.6 %) patients and 54 (94.4%) of the patients had complete cure.

**Conclusion:** Preliminary Seton followed by fistulectomy and sphincteroplasty has shown to be highly effective in treating transsphincteric and complex fistulas with low recurrence rates (2/56=3.6%) and no risk of subsequent incontinence.

**Keywords:** anal fistula; seton; fistulectomy.

## I. INTRODUCTION

The aim of surgical treatment of anal fistulas is to cure the disease by preventing recurrence while ensuring that faecal continence is maintained. Normally, a 'lay-open' fistulotomy or fistulectomy technique is used for inter-sphincteric or low trans-sphincteric fistulas, but high trans-sphincteric or supra-sphincteric fistulas would require division of a large portion of the external sphincter, thereby increasing the chance of faecal incontinence. Many procedures have been described. Current management remains dependent on surgeon preference between options like fistulotomy, fistulectomy, loose or cutting Seton insertion, advancement flaps, fibrin glue or anal plugs with variable results.

The use of Seton in the treatment of anal fistulas has been ongoing for centuries. One of the earliest

papers written by Hippocrates in 400 BC described fistulotomy as well as the use of a cutting Seton made of horse hair wrapped with lint threads<sup>1</sup>.

The Seton works by several mechanisms. Firstly, it helps to identify and mark the fistulous tract. Secondly, it promotes fibrosis in the surrounding tissue. Thirdly, it encourages drainage and prevents formation of new abscesses. And finally it decreases the risk of incontinence as scarring prevents retraction of the sphincter.

Seton can be used for long term palliation to avoid septic and painful exacerbations by establishing effective drainage; most often in patients with Crohn's disease<sup>2</sup> or it can be used as part of a staged fistulectomy before use of advanced techniques (fistulectomy, advancement flap). Such strategy protects against the consequences of cutting the sphincter. The goal of this study is to report our experience in treating anal fistulas using the preliminary Seton technique before fistulectomy and compare the safety and efficacy of reduction of incontinence and recurrence in this method as compared to other methods in the literature.

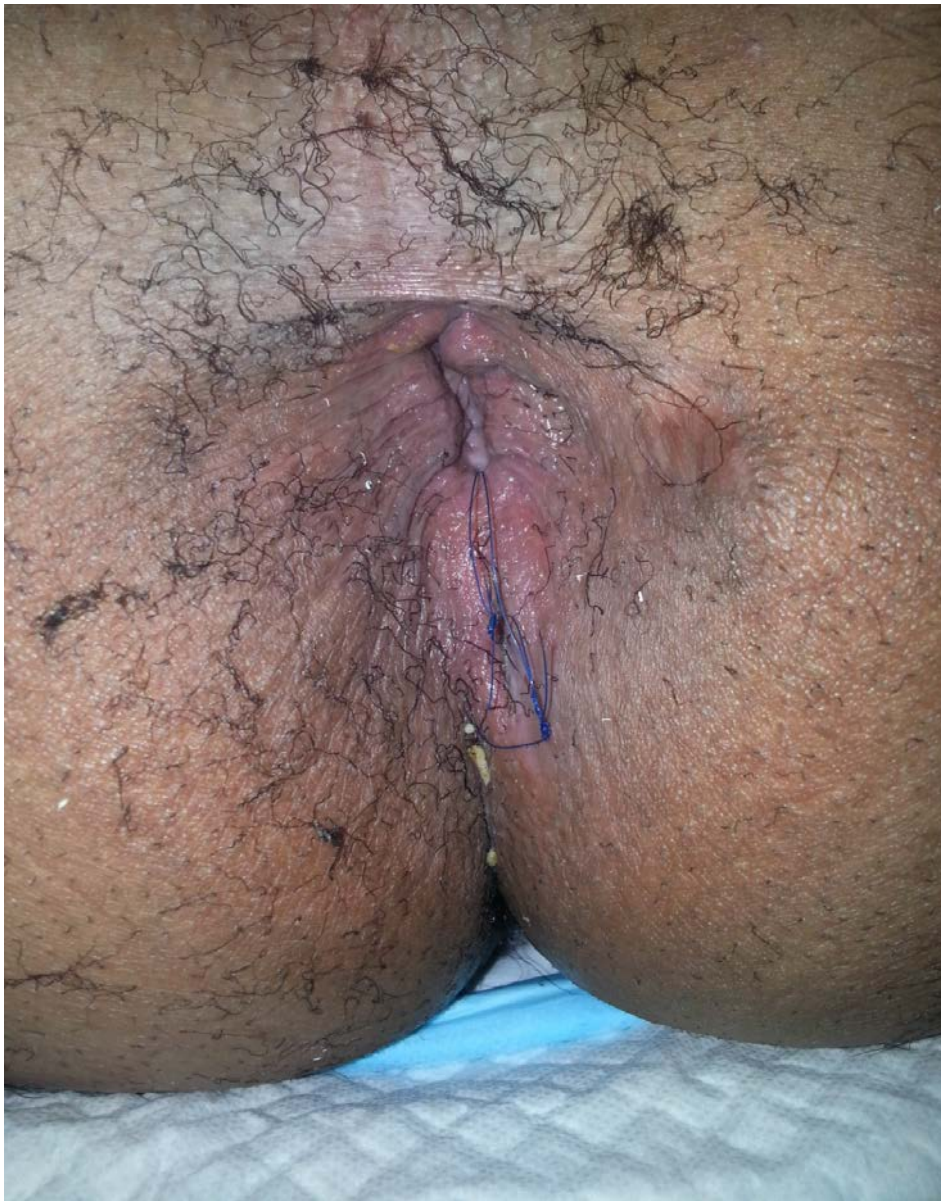
## II. METHOD

Data collected from the records of 56 patients who underwent preliminary Seton placement followed 2-4 months later by fistulectomy and sphincter repair during the period of March 2011 — March 2013. Fistulae were characterized using Parks' classification. Perianal fistulas were defined as complex if they had multiple external openings, high fistulas if the internal opening which was at the level of the dentate line and low fistulas if the internal opening was below the dentate line. Patients with concomitant anal pathology and patients with inflammatory bowel disease were excluded from the study.

Autho <sup>α</sup> § : Rashid Hospital Dubai Health Authority.  
e-mails: lsalozaibi@gmail.com, aaljaziri@dha.gov.ae

The entire procedure was performed under general anaesthesia with the patient in the lithotomy position. After initial evaluation, the external and internal openings were located using a probe and air injection

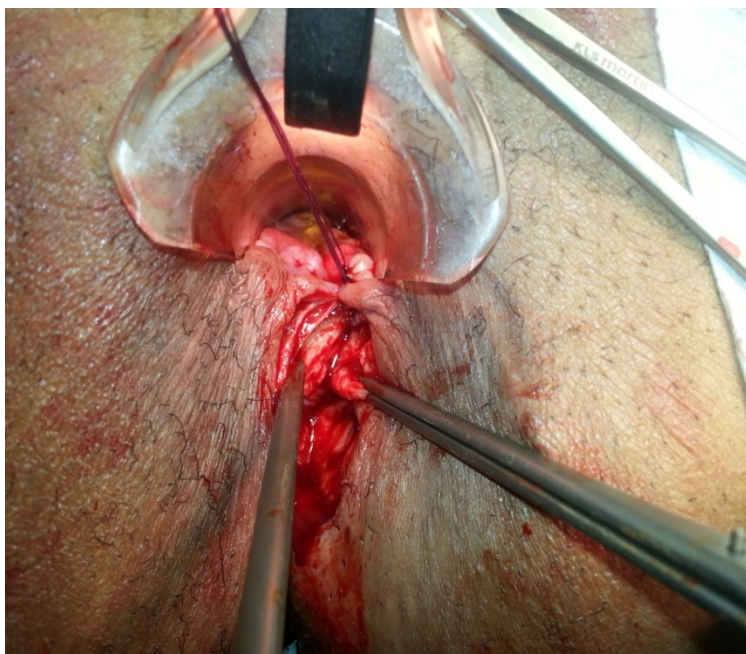
along the track. A loose Seton using 2 braided, non-absorbable sutures (4/0 prolene) was looped around the fistula tract, (Figure 1). It was not tightened at any time during the follow-up and was not removed.



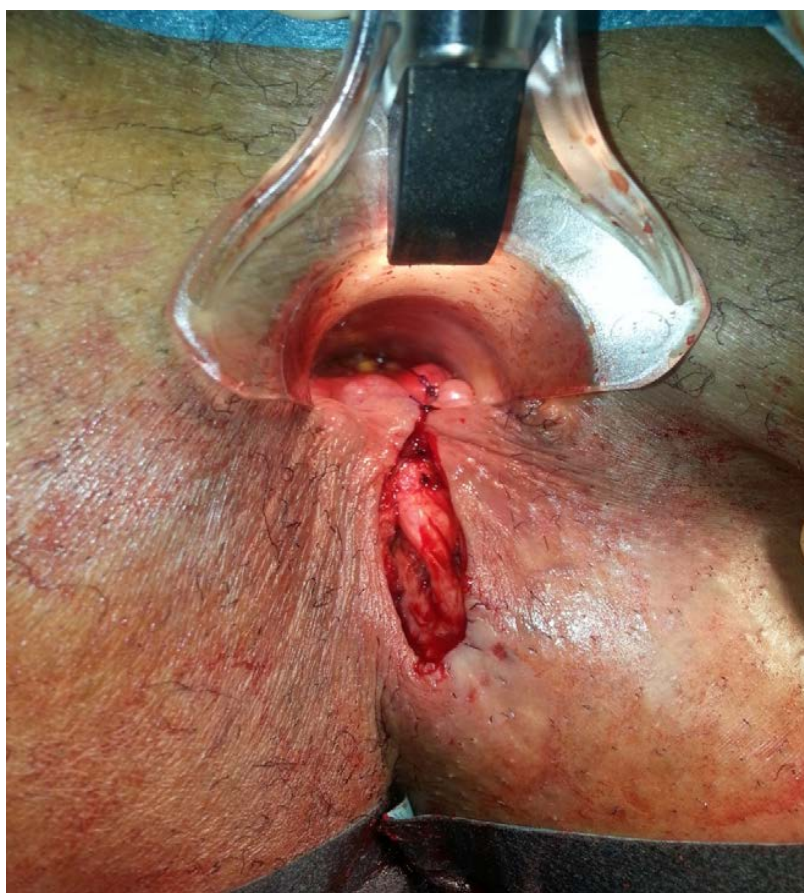*Figure 1 : Seton in situ*



2-4months later the fistula was completely excised with immediate repair of the sphincters and the wound kept open,(Figure 2a, b).



*Figure 2a* : After fistulectomy showing the sphincters before repair



*Figure 2b* : After the sphincter repair

During a follow-up period of 12-36 months details of healing (i.e. no signs of discharge), recurrence, and complications were gathered. Patients were followed up at the clinic after 1 week, 3 months and after 1 year. Continence was evaluated according to Cleveland Clinic score<sup>3</sup>. The excised fistulas were sent for histopathology to rule out inflammatory bowel disease or cancer.

The data were analyzed using IBM SPSS STATISTICS BASE 21.

### III. RESULTS

After obtaining the ethical committee approval, the record of 56 patients with transsphincteric and complex anal fistula who were managed with preliminary loose Seton followed by fistulectomy and sphincteroplasty were reviewed. Fifty-four (96.4%) of the patients were men and Two (3.6%) were women. The overall mean age was 39.5 (range 25-61). The types of fistulas are depicted in Table 1.

*Table 1 : Type of fistulas*

Type of Fistula	Number	Percent
Low transsphincteric	31	55
High transsphincteric	9	16
Complex	16	29
Total	56	100

Twenty-nine (52%) of the patients gave history of previous surgery, 25(45%) had incision & drainage of perianal abscesses and four (7%) had previous fistula surgery. The entire procedure was done under general anaesthesia. Preliminary Seton insertion was done as a day case surgery. The Seton was kept in situ for a period of 2-5 months (average 2.6M). The second procedure was fistulectomy and sphincter repair for which 49 (88%) were done as a day case surgeries.

The mean follow up was 20.5 months (12-36 months). Six (10.7%) patients experienced post-operative pain which required analgesia while three (5.3%) developed bleeding; requiring surgery in one patient and only pressure dressing in the other two. The complete wound healing time (i.e. no more need for wound dressing) was between 2-8 weeks (mean 3.7 weeks).

While two patients (3.6%) reported a transient incontinence of gas in the immediate postoperative period (score 3 and 4, respectively according to the Cleveland Incontinence Score), which lasted for 3 months there was no incontinence in any of the patients in the longer follow up. The fistulas were completely cured in 54(96.4%) of patients. Recurrence occurred in two patients (3.6%); one was re-operated again for which the same procedure was repeated again -loose Seton for 4 months followed by fistulectomy and sphincter repair- and during the follow up he didn't show any signs of recurrence while the other patient did not

attend the follow up; he was contacted by phone and reported that he had been re-operated on in another hospital but six months later he had recurrence.

### IV. DISCUSSION

Surgical treatment of fistula-in-ano is associated with the risk of incontinence and recurrence. Several operative techniques were established to reduce these complications but till today none has been shown to be 100% successful. Post-operative anal incontinence after fistulotomy has been reported to be 20.3%<sup>4</sup>. Arroyo A et al<sup>5</sup>, who combined fistulotomy with sphincter reconstruction concluded that continence were improved in incontinent patients and were not jeopardized in continent ones. The patients who reported postoperative incontinence in his study were 16.6%. Several risk factors are associated with the postoperative incontinence, including recurrent or complex fistulas, multiple previous drainages<sup>6</sup>, and type of operative procedure<sup>7</sup>.

In a prospective audit, Sileri P et al<sup>8</sup> demonstrated that a high number of complex anal fistulae has been treated by seton placement and a good outcome was achieved in the majority of patients. The selection of Seton type and technique depends on surgeon preference. Gokulakrishna Subhas et al<sup>9</sup> described all the available variations in materials and techniques for seton treatment.

The use of loose Seton alone in the treatment of complex anal fistulas has been reported in several studies with variable results. Some patients were cured by this technique but the success rate tumbled over time. This approach avoids the risk of incontinence complications that may arise due to division of the external sphincter but many patients develop further sepsis that usually requires surgery<sup>10</sup>.

The use of Seton drainage before definitive surgery has been used in an attempt to decrease the risk of incontinence and recurrence. Several reports have found Seton to be safe, with low incidence of recurrence and incontinence. Different surgeons use the Seton in different ways. Russell K et al<sup>11</sup>, performed staged fistulotomy using a Seton. They applied the Seton around the distal half of the intact external sphincter after dividing the cephalad portion of the tract; followed 6-8 weeks later by dividing of the remaining external sphincter, and a recurrence rate of 3% was noted. Kennedy and Zegarra<sup>12</sup> did the same first stage fistulotomy and Seton placement but in the second stage the Seton was removed rather than performing the second stage division of muscles. It minimized the risk of incontinence and primary healing occurred in 78%. Fung AK et al<sup>13</sup> also used the technique of laying open the subcutaneous tract and insertion of loose seton for the part of the tract related to the sphincter complex which was removed after a median length of 7 months

with a recurrence rate of 19%. In the study by Ratto C et al<sup>14</sup>, he used Seton drainage in 40.3% of the patients followed later by fistulotomy and end to end primary sphincteroplasty. There was no significant change in the fecal incontinence score and the fistula recurrence was observed in 3 out of 72 patients (4.3%). Pearl RK et al<sup>15</sup> reported that a staged fistulotomy using a Seton is a safe and effective method of treating high or complicated anorectal fistulas with major incontinence of 5% and a recurrence rate of 3%.

An alternative technique for treating complex, high transsphincteric anal fistulas using the Seton was reported in the studies of Subhas G et al<sup>16</sup> and GalisRozen et al<sup>17</sup>. Patients were asked to rotate the Seton daily, one revolution in each direction, pulling the knot through the fistula tract. The progressive migration technique resulted in the gradual healing and eradication of the fistula tract in 75% of patients, with no recurrence (Setons completely worked their way to the surface, or tract migration was extensive enough to allow a safe completion fistulotomy).

Loose Seton is preferable to the cutting Seton; the later procedure yields fairly good results in regards to curing the fistula but it's painful, may result in pressure necrosis of the full thickness of the sphincter muscle resulting in sepsis and increases rate of anal incontinence<sup>18</sup>.

## V. CONCLUSION

Preliminary Seton followed by fistulectomy and immediate sphincter repair has shown to be highly effective in treating transsphincteric and complex fistulas with low recurrence rate (2/56=3.6%) and no risk of subsequent incontinence in the population we studied.

## REFERENCES RÉFÉRENCES REFERENCIAS

- Adams F. **The genuine works of Hippocrates.** London: C and J Adlard; 1849. p. 816-9.
- Takesue Y, Ohge H, Yokoyama T, Murakami Y, Imamura Y, Sueda T. **Long term results of seton drainage on complex anal fistulae in patients with Crohn's disease.** J Gastroenterol (2002); 37(11):912-5.
- Jorge JM1, Wexner SD. **Etiology and management of fecal incontinence.** Dis Colon Rectum. 1993 Jan; 36(1):77-97.
- Takayuki T., Makoto M., Takashi K., et al. **Factors affecting continence after fistulotomy for intersphincteric fistula in ano.** Int J Colorectal Dis (2007) 22:1071-1075.
- Arroyo A, Perez-Legaz J, Moya P, et al. **Fistulotomy and sphincter reconstruction in the treatment of complex fistula in ano: long-term clinical and manometric results.** Ann Surg. (2012) May; 255(5):935-9.
- Jordan J., Roig JV., Garcia-Armengol J., Garcia-Granero E., Solana A., **Risk factors for recurrence and incontinence after anal fistula surgery.** Colorectal Dis (2010) Mar; 12(3):254-60.
- Garcia-Aguilar J, Belmonte C, Wong WD, Goldberg SM, Madoff RD. **Anal fistula surgery: Factors associated with recurrence and incontinence.** Dis Colon Rectum (1996) Jul; 39(7):723-729.
- Sileri P, Cadeddu F, D'Ugo S, Franceschilli L. **Surgery for fistula-in-ano in a specialist colorectal unit: a critical appraisal.** BMC Gastroenterol (2011) Nov 9; 11:120.
- Gokulakrishna Subhas, Jasneet SB, Ahmed A, Amruta U. **Setons in the treatment of anal fistula: Review of variations in material and techniques.** Dig Surg (2012); 29:292-300.
- Buchanan GN, Owen HA, Torkington J, Lunniss PJ, Nicholls RJ, Cohen CR. **Long-term outcome following loose-seton technique for external sphincter preservation in complex anal fistula.** Br J Surg. (2004) Apr; 91(4):476-80.
- Russell K, John R, Charles P, Robert I, M. Leela, Richard L, Jose R, Hernad A. **Role of the seton in the management of anorectal fistulas.** Dis Colon Rectum, June (1993) Vol.36, No.6.
- Kennedy HL, Zegarra JP. **Fistulotomy without external sphincter division for high anal fistula.** Br J Surg (1990); 77:898-901.
- Fung AK, Card GV, Ross NP, Yule SR, Aly EH. **Operative strategy for fistula-in-ano without division of the anal sphincter.** Ann R Coll Surg Engl. (2013) Oct; 95(7):461-467.
- Ratto C, Litta F, Parello A, Zacccone G, Donisi L, De Simone V. **Fistulotomy with end to end primary sphincteroplasty for anal fistula: results from a prospective study.** Dis Colon Rectum. (2013) Feb; 56(2):226-33.
- Pearl RK, Andrews JR, Orsay CP, Weisman RI, Prasad ML, Nelson RL, Cintron JR, Abcarian H. **Role of the seton in the management of anorectal fistulas.** Dis Colon Rectum. (1993) Jun; 36(6):573-7.
- Subhas G, Gupta A, Balaraman S, Mittal VK, Pearlman R. **Non-cutting setons for progressive migration of complex fistula tracts: a new spin on an old technique.** Int J Colorectal Dis. (2011) Jun; 26(6):793-8.
- Galis-Rozen E, Tulchinsky H, Rosen A, Eldar S, Rabau M, Stepanski A, Klausner JM, Ziv Y. **Long-term outcome of loose seton for complex anal fistula: a two-centre study of patients with and without Crohn's disease.** Colorectal Dis. (2010) Apr; 12(4):358-62.
- Hämäläinen KP, Sainio AP. **Cutting seton for anal fistulas: high risk of minor control defects.** Dis Colon Rectum 1997; 40:1443.