

Polycythemia with Cerebellar Hemangioblastoma

Elizabeth Jeya Vardhini Samuel¹

¹ Pondicherry Institute of Medical Sciences

Received: 11 February 2015 Accepted: 5 March 2015 Published: 15 March 2015

Abstract

56 year old male presented with one month history of vomiting with abdominal pain; hemogram suggested polycythemia with hemoglobin of 16.5-18.1gm

Index terms— polycythemia, cerebellar hemangioblastoma.

1 Polycythemia with Cerebellar Hemangioblastoma

Elizabeth JeyaVardhini Samuel ?, Nagarajan Natarajan ?, Ramesh ? & Latha M ? Abstract-56 year old male presented with one month history of vomiting with abdominal pain; hemogram suggested polycythemia with hemoglobin of 16.5-18.1gm%, gastroscopy showed pan gastritis, bone marrow smear, biopsy showed erythroid, megakaryocytic hyperplasia;ultra sonogram abdomen, pelvis did not show any significant abnormality; patient improved with parenteral hydration, proton pump inhibitors; after ~7 months he returned with weakness, weight loss; hemoglobin alone had increased to 19 to 20gm%, with a hematocrit of 56.1%, other cell lines were not involved, suggesting secondary polycythemia; CT scan brain revealed Cerebellar Hemangioblastoma with obstructive hydrocephalus; emergency ventriculo peritoneal shunt was performed, followed by excision of the tumor; patient recovered and hemoglobin normalized.

Keywords: polycythemia, cerebellar hemangioblastoma.

6 year old male presented with vomiting, upper abdominal pain of ~30 days duration, associated with mild weight loss; he was a known hypertensive on irregular treatment but not a diabetic; he was a non smoker, non ethanol consumer, he used snuff, his wife had undergone permanent sterilization. General examination showed medium built middle aged male, with moderate dehydration, but no pallor, icterus, lymphadenopathy or pedal edema; his blood pressure measured 150/100 mm Hg; cardiovascular system, respiratory systems showed no abnormality; he was conscious oriented, with no neurological deficit; epigastrium showed tenderness, without guarding or rigidity; there was no hepatosplenomegaly.

His initial hemoglobin was 18gm%, with hydration the hemoglobin reduced to 16.5 to 17 gm%; liver function tests showed mild elevation of transaminase to 42 mg/dl, renal parameters were normal; peripheral smear showed reactive lymphocytosis, normochromic, normocytic red blood cells, with normal white blood cells, adequate platelets. Ultra sonogram of the abdomen showed simple renal cortical cysts, fatty change liver. Oesphago gastro duodenoscopy showed pan gastritis; bone marrow biopsy done to evaluate for reactive lymphocytosis, with suspicious borderline polycythemia, showed hyper cellular marrow with erythroid, megakaryocytic hyperplasia.

He received treatment with proton pump inhibitors, parenteral hydration; patient's vomiting stopped, his abdominal pain improved and he requested discharge due to personal reasons. 6-7 months later patient returned with weakness, debility, for the past >30 days duration with obvious weight loss; examination suggested subtle Cerebellar signs, with suspicious, mild nystagmus on looking to the left side, suspicious impairment of tandem walking, there was no other neurological deficit; investigations revealed hemoglobin of 19.5 to 20 gm%, hematocrit of 56.1%, other cell lines were normal; the weight loss was very significant ~50%; since true secondary polycythemia was suggested by pure erythrocytosis without involving the other cell lines, ultra sonogram abdomen was normal, with significant weight loss, computerized axial tomography scan of brain was planned, to assess for Cerebellar Hemangioblastoma, probably having resulted in secondary polycythemia.

Computerized axial Tomography scan of the brain showed a 3.5cm × 3.8 cm mass lesion, with cystic areas, suggesting a possibility of Hemangioblastoma, with complete effacement of 4 th ventricle, seen to cause obstructive hydrocephalus of the 3 rd and both lateral ventricles; retinal examination showed papilloedema, but

3 IV. ACKNOWLEDGEMENTS

47 no hemangiomas; Magnetic resonance imaging of the brain showed solid, cystic mass in vermis, left Cerebellar
48 hemisphere, to cause obstructive hydrocephalus Figure 1. Emergency ventriculo peritoneal shunt was done
49 followed by tumor excision by sub occipital craniectomy; post operative period was uneventful;

50 Histopathological examination of the excised tumor showed two components of the tumor-vascular and stromal;
51 vascular component is in the form of network of capillaries and large thin walled vascular spaces; stromal
52 component showed vacuolated large stromal cells with round to oval bland nuclei; occasional enlarged nuclei
53 were seen; sparse mitoses were seen; foci of hyalinized vascular stroma were noted; tumor parenchyma interface
54 was discrete in many foci, while creeping tumor was seen in occasional foci; capillary Hemangioblastoma-WHO
55 grade 1 was reported Figure 2. Polycythemia refers to high hemoglobin greater than upper limit of normal,
56 in adult females $>16.5\text{gm}\%$ or hematocrit >0.48 , in adult males hemoglobin of $18.8\text{gm}\%$ or hematocrit >0.52
57 due to increase number of red blood cells [true polycythemia] or reduction in blood volume [apparent, relative
58 polycythemia].

59 Causes of true polycythemia are 1 primary polycythemia-a myeloproliferative disorder e.g. Polycythemia
60 Rubra Vera; secondary true polycythemia due to increased secretion of erythropoietin secondary to tissue hypoxia
61 as in high altitude, lung disease, cyanotic heart disease, high affinity hemoglobin, or secondary polycythemia
62 due to inappropriately increased erythropoietin secretion by renal diseases such as hydronephrosis, cysts,
63 carcinoma, other tumors like bronchogenic carcinoma, uterine fibroids, hepatoma, pheochromocytoma, Cerebellar
64 Hemangioblastoma.

65 Polycythemia Rubra Vera is a 2 clonal disorder involving a multipotent hematopoietic progenitor cell in which
66 phenotypically normal red blood cells, granulocytes and platelets accumulate in the absence of a recognizable
67 stimulus.

68 Since the patient had significant weight loss with true polycythemia in the second visit, not involving the other
69 cells of granulocytes, and platelets, secondary polycythemia was considered; since ultra sonogram of the abdomen
70 did not show any abnormality, search for tumors including Cerebellar Hemangioblastoma was undertaken.

71 Hemangioblastoma are rare benign tumors that occupy central 3 nervous system and other regions like kidney,
72 liver, pancreas; the incidence among posterior fossa tumors averages 11%; highest incidence is in 3 rd t o 6 th
73 decades of life; family history is significant with autosomal dominant inheritance, related to deletion of tumor
74 suppressor gene, on the short arm of chromosome 3 .

75 Hemangioblastoma are benign vascular tumors that arise from embryonic remnants of mesoderm origin,
76 trapped in nervous system, during first trimester 4 of life Cerebellar Hemangioblastoma a rare cause of 5
77 erythrocytosis, consequent to ectopic production of erythropoietin by the tumor cells.

78 2 cases of Hemangioblastoma followed up long term showed malignant 6

2 III. Conclusion

79 56 year old male presented with spurious or relative polycythemia suspect, later on progressed to true secondary
80 polycythemia with significant weight loss, prompting a search for neoplasms; clinically he had subtle Cerebellar
81 signs and imaging confirmed the diagnosis of Cerebellar Hemangioblastoma, with associated obstructive
82 hydrocephalus; emergency ventriculo peritoneal shunt followed by excision of the tumor was performed and
83 the histopathological evaluation confirmed WHO grade 1 Cerebellar Hemangioblastoma; hemoglobin normalized
84 with excision of the tumor.
85

3 IV. Acknowledgements

86 The needful expert services of Neurosurgery, General pathology, Radiology colleagues is deeply acknowledged
87 with gratitude.
88

89 Hemangioblastoma is a tumor of the central nervous system, arising from vascular system, and can be present
90 in retina 7 8 9 10 and spinal cord; can be associated with polycythemia, pancreatic cysts and Von Hippel Lindau
91 syndrome.

92 As per the corresponding Authors earlier publications, couples observing contraception have 4-7 fold 11
93 increase in tumors, cancers, among 35->50years of age, by fragmentation of the germ cells with associated
94 decreased surveillance by estrogen, androgen 12 resulting in uncontrolled proliferation of any cell, preceded
95 by no differentiation, resulting in neoplasms. If only the wife's permanent sterilization can be reversed by tubal
96 recanalization by awareness, financial aid, surgical expertise, the germ cells destruction will stop and the androgen,
97 estrogen 13 will return to 79.9% of age normal, restoring genomic repertoire, cell cycle of differentiation, followed
98 by controlled multiplication, so that recurrence and malignant transformation of the tumor will be curtailed.



Figure 1: Figure 1 :

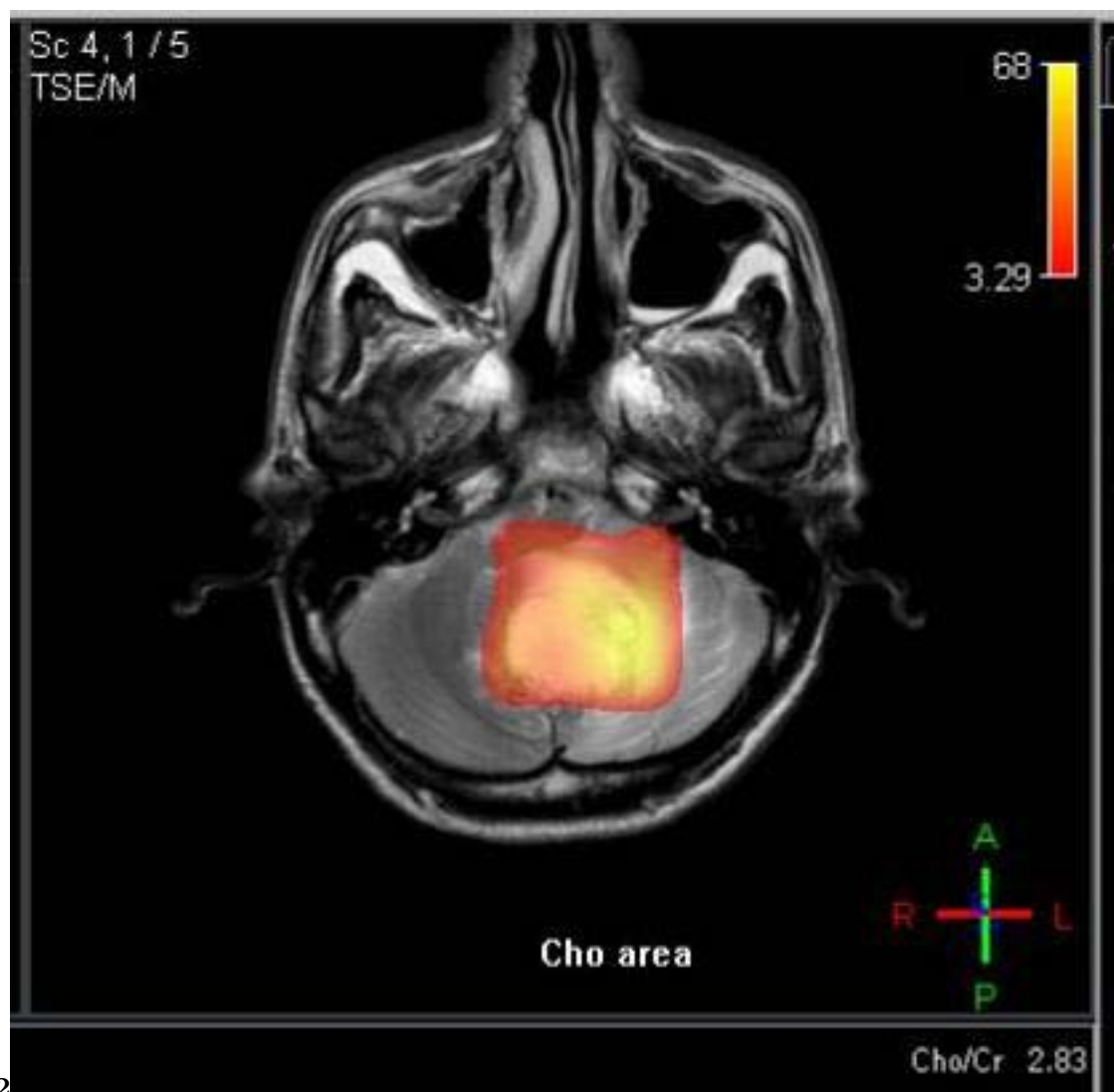

Figure 2: Figure 2 :

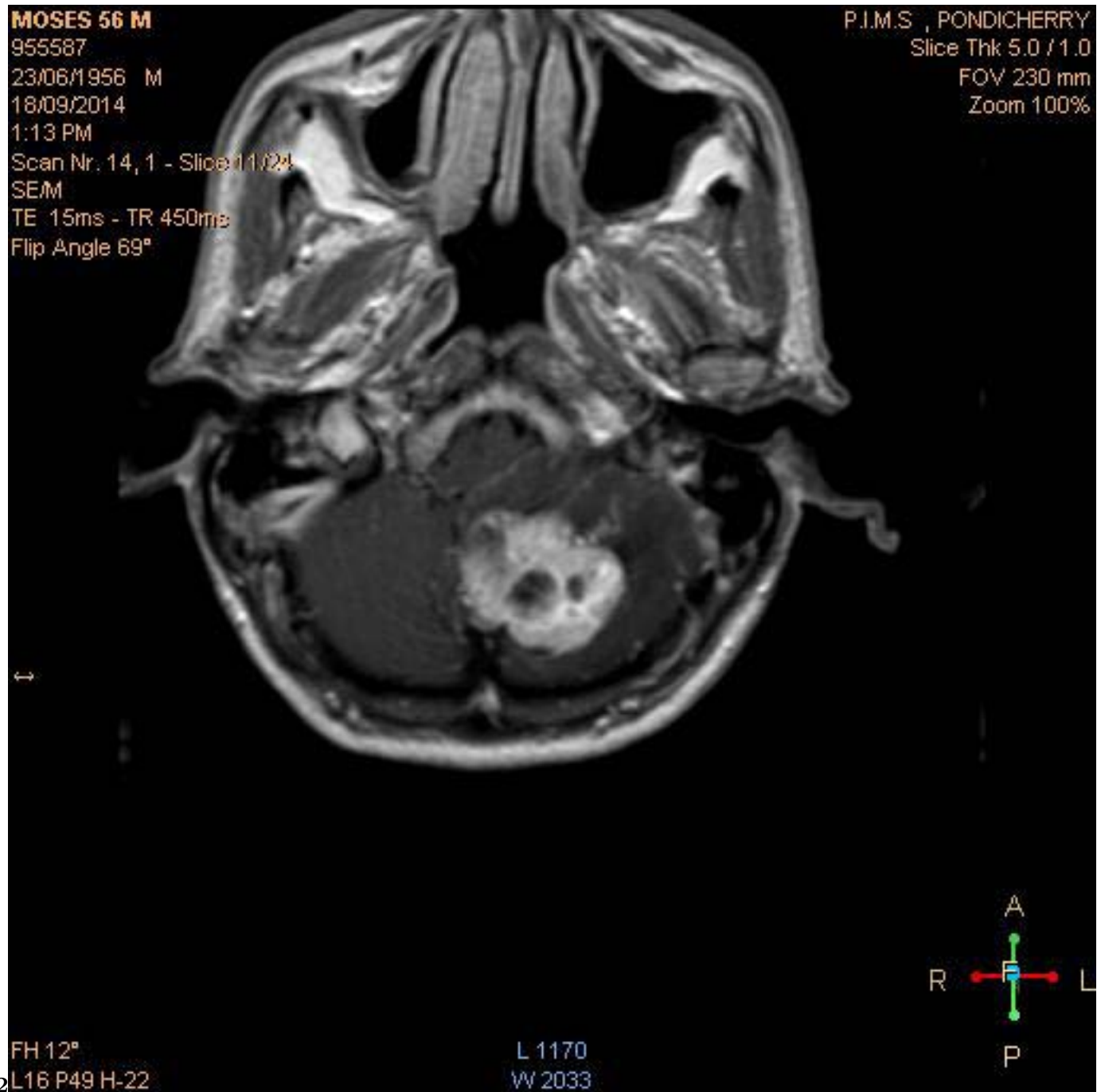


Figure 3: Figure 2 :

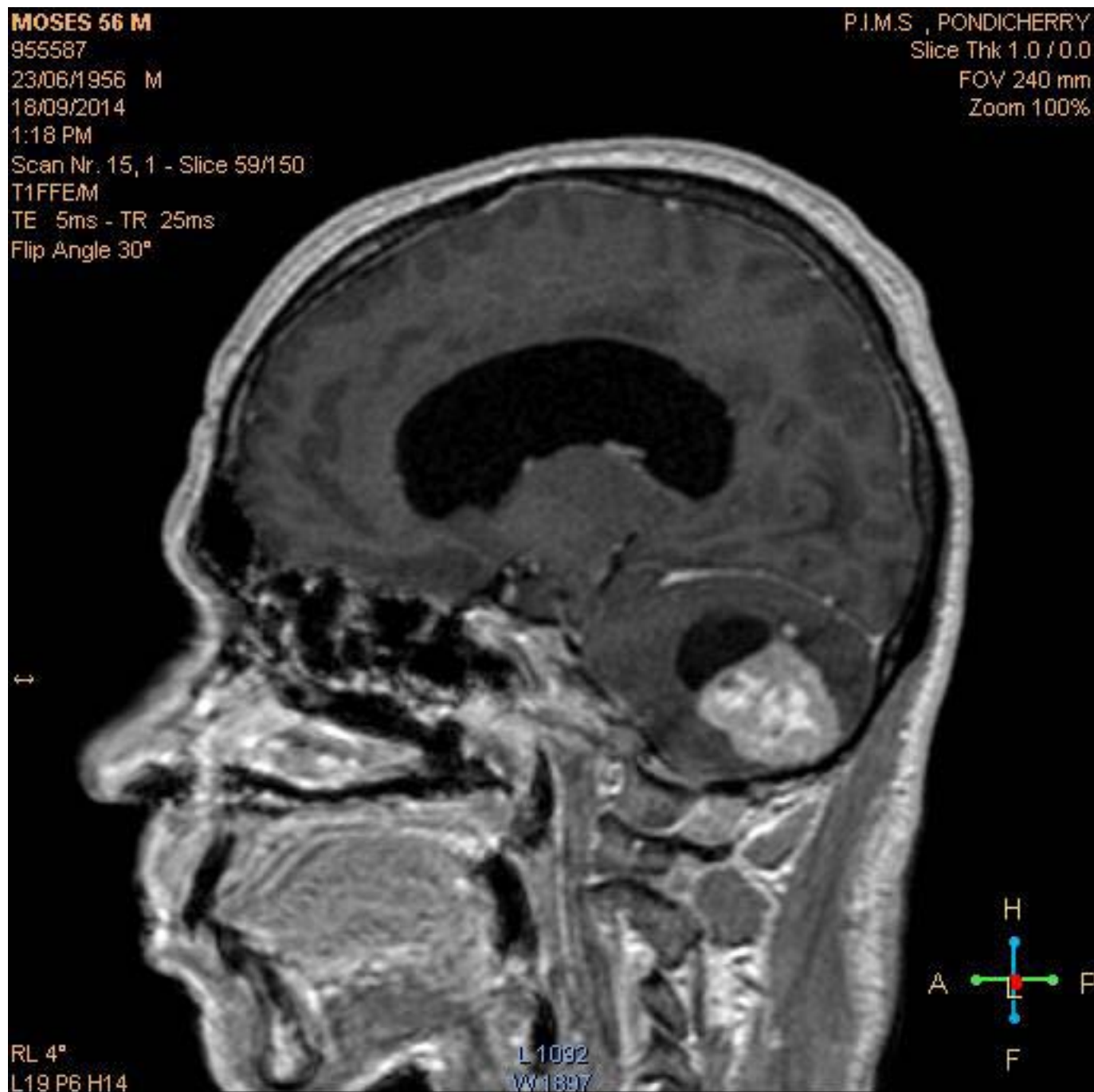


Figure 4:

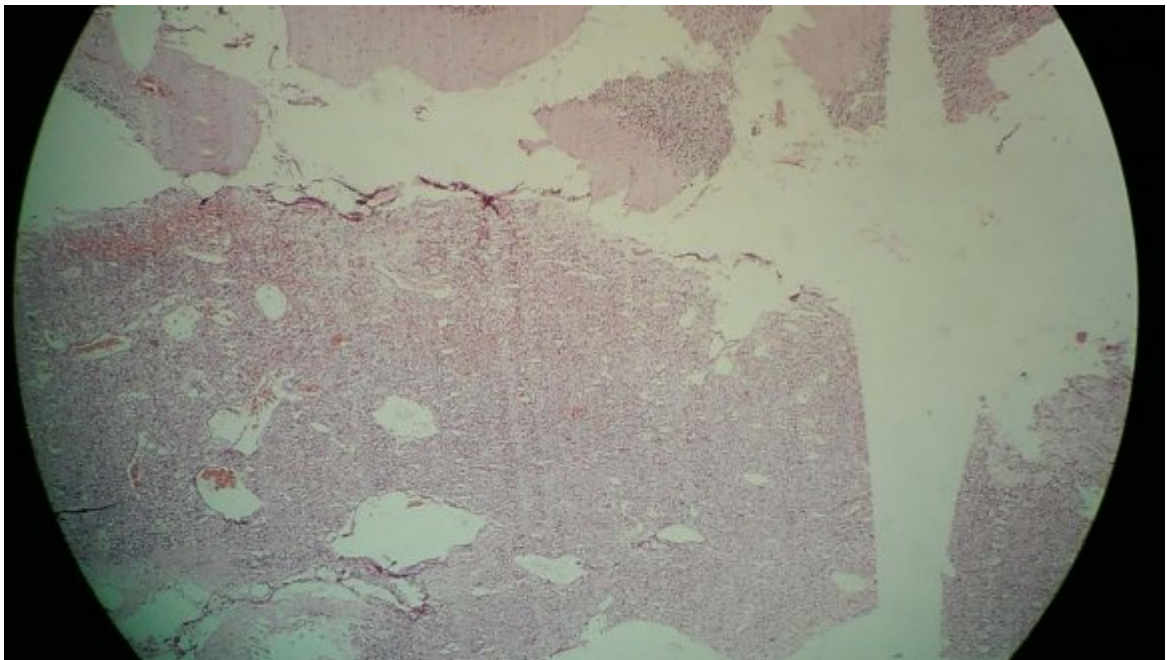


Figure 5:

-
- 99 [Craig et al.] , J O Craig , H G McClelland , Watson . Polycythemia.
100 [American Journal of Hematology] , *American Journal of Hematology* 71 p. .
101 [Références] , Références .
102 [Acta Neurochirurgica ()] , *Acta Neurochirurgica* 1984. 71 p. .
103 [Seung Hwan Lee et al. (2010)] , Bong Jin Seung Hwan Lee , Sung Park , Young Jin Kim , Lim . *Journal of*
104 *Korean Neurosurgical society* 2010. September 48. (3) .
105 [Elizabeth (2014)] ‘Abortion, Contraception Reversal-Medical Miracle-Autologous Germ cells replant-Decline in
106 global degenerative, autoimmune, neoplastic, infectious diseases; decline in rising environmental estrogen
107 [equating with aborted blood pollution] and decline in depletion of ozone’. J S Elizabeth . ISSN: 2279- 0861.
108 *IOSR Journal of Dental and Medical Sciences IOSR- JDMS* e-: 2279-0853. Sep. 2014. 13 (9) p. .
109 [Chichiu et al.] S O Chichiu , Lu En-Cheong , Ho . *Polycythemia secondary to Cerebellar Hemangioblastoma,*
110 [Davidson’s Principles and practice of Medicine ()] *Davidson’s Principles and practice of Medicine*, 2010. p. . (21
111 st edition)
112 [Elizabeth ()] J S Elizabeth . 10.4236/ojpm.2014.47070. [http://www.scirp.org/journal/ojpmhttp://](http://www.scirp.org/journal/ojpmhttp://dx.doi.org/10.4236/ojpm.2014.47070)
113 dx.doi.org/10.4236/ojpm.2014.47070 *Cancer and Germ cells; OJPM*, 2014. 4 p. .
114 [Ferranti et al.] L Ferranti , Celli , Fraioliand , Santoro . *Hemangioblastoma of the posterior cranial fossa,*
115 [HMFarrukh: Cerebellar Hemangioblastoma presenting as secondary erythrocytosis West J Med (1996)]
116 ‘HMFarrukh: Cerebellar Hemangioblastoma presenting as secondary erythrocytosis’. *West J Med* Feb.
117 1996. 164 (2) p. .
118 [Elizabeth (2014)] ‘Increased prevalence of Renal Diseases-Metabolic syndrome and fragmented germ cells with
119 reduced Endogenous Estrogen’. J S Elizabeth . *Androgen International Journal of Innovative Research and*
120 *Studies* Sep 2014. 3 p. .
121 [Lindsay et al. ()] ‘Neurology and Neurosurgery illustrated United States Churchill Livingstone 10’. Kenneth W
122 Lindsay , Ian Bone , Robin Callander , Van Gijn . doi: 10.1016/ j.ddmec.2005.04.003. *Von Hippel Lindau*
123 *associated malignancies; Drug discovery today, Disease mechanism*, 1991. 2005. 2 p. . (Kaelin)
124 [Jerry and Spivak ()] *Polycythemia Vera, Harrison’s Principles of Internal Medicine*, L Jerry , Spivak . 2012. 1
125 p. 898. (18 th edition)
126 [Louis ()] *WHO classification of tumors of the CNS*, David N Louis . 1991.