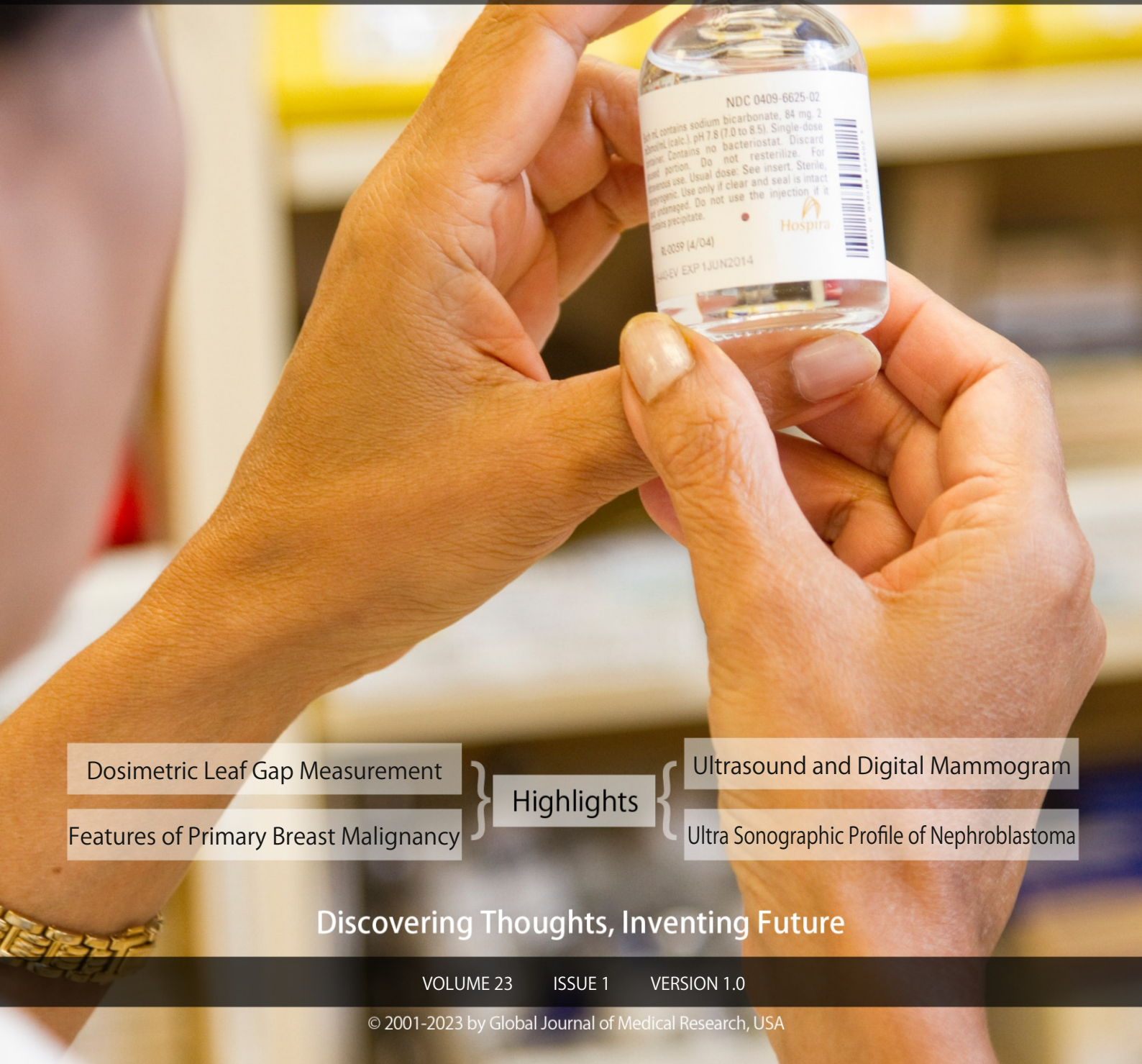

GLOBAL JOURNAL

OF MEDICAL RESEARCH: D

Radiology, Diagnostic Imaging and Instrumentation



NDC 0409-6625-02
Each mL contains sodium bicarbonate, 84 mg, 2
mEq (calc.) pH 7.8 (7.0 to 8.5). Single-dose
use. Contains no bacteriostat. Discard
unused portion. Do not resterilize. For
intravenous use. Usual dose: See insert. Sterile,
nonpyrogenic. Use only if clear and seal is intact
and undamaged. Do not use the injection if it
contains precipitate.
Hospira
R-0059 (4/04)
EXP 1 JUN 2014

Dosimetric Leaf Gap Measurement	}	Highlights	}	Ultrasound and Digital Mammogram
Features of Primary Breast Malignancy				Ultra Sonographic Profile of Nephroblastoma

Discovering Thoughts, Inventing Future

VOLUME 23 ISSUE 1 VERSION 1.0



GLOBAL JOURNAL OF MEDICAL RESEARCH: D
RADIOLOGY, DIAGNOSTIC, IMAGING AND INSTRUMENTATION



GLOBAL JOURNAL OF MEDICAL RESEARCH: D
RADIOLOGY, DIAGNOSTIC, IMAGING AND INSTRUMENTATION

VOLUME 23 ISSUE 1 (VER. 1.0)

OPEN ASSOCIATION OF RESEARCH SOCIETY

© Global Journal of Medical Research. 2023.

All rights reserved.

This is a special issue published in version 1.0 of "Global Journal of Medical Research." By Global Journals Inc.

All articles are open access articles distributed under "Global Journal of Medical Research"

Reading License, which permits restricted use. Entire contents are copyright by of "Global Journal of Medical Research" unless otherwise noted on specific articles.

No part of this publication may be reproduced or transmitted in any form or by any means, electronic or mechanical, including photocopy, recording, or any information storage and retrieval system, without written permission.

The opinions and statements made in this book are those of the authors concerned. Ultraculture has not verified and neither confirms nor denies any of the foregoing and no warranty or fitness is implied.

Engage with the contents herein at your own risk.

The use of this journal, and the terms and conditions for our providing information, is governed by our Disclaimer, Terms and Conditions and Privacy Policy given on our website <http://globaljournals.us/terms-and-condition/menu-id-1463/>

By referring / using / reading / any type of association / referencing this journal, this signifies and you acknowledge that you have read them and that you accept and will be bound by the terms thereof.

All information, journals, this journal, activities undertaken, materials, services and our website, terms and conditions, privacy policy, and this journal is subject to change anytime without any prior notice.

Incorporation No.: 0423089
License No.: 42125/022010/1186
Registration No.: 430374
Import-Export Code: 1109007027
Employer Identification Number (EIN):
USA Tax ID: 98-0673427

Global Journals Inc.

(A Delaware USA Incorporation with "Good Standing"; **Reg. Number: 0423089**)

Sponsors: *Open Association of Research Society*

Open Scientific Standards

Publisher's Headquarters office

Global Journals® Headquarters
945th Concord Streets,
Framingham Massachusetts Pin: 01701,
United States of America

USA Toll Free: +001-888-839-7392

USA Toll Free Fax: +001-888-839-7392

Offset Typesetting

Global Journals Incorporated
2nd, Lansdowne, Lansdowne Rd., Croydon-Surrey,
Pin: CR9 2ER, United Kingdom

Packaging & Continental Dispatching

Global Journals Pvt Ltd
E-3130 Sudama Nagar, Near Gopur Square,
Indore, M.P., Pin:452009, India

Find a correspondence nodal officer near you

To find nodal officer of your country, please
email us at local@globaljournals.org

eContacts

Press Inquiries: press@globaljournals.org
Investor Inquiries: investors@globaljournals.org
Technical Support: technology@globaljournals.org
Media & Releases: media@globaljournals.org

Pricing (Excluding Air Parcel Charges):

Yearly Subscription (Personal & Institutional)
250 USD (B/W) & 350 USD (Color)

EDITORIAL BOARD

GLOBAL JOURNAL OF MEDICAL RESEARCH

Dr. Apostolos Ch. Zarros

DM, Degree (Ptychio) holder in Medicine,
National and Kapodistrian University of Athens
MRes, Master of Research in Molecular Functions in
Disease, University of Glasgow FRNS, Fellow, Royal
Numismatic Society Member, European Society for
Neurochemistry Member, Royal Institute of Philosophy
Scotland, United Kingdom

Dr. Alfio Ferlito

Professor Department of Surgical Sciences
University of Udine School of Medicine, Italy

Dr. Jixin Zhong

Department of Medicine, Affiliated Hospital of
Guangdong Medical College, Zhanjiang, China, Davis
Heart and Lung Research Institute, The Ohio State
University, Columbus, OH 43210, US

Rama Rao Ganga

MBBS
MS (University of Health Sciences, Vijayawada, India)
MRCS (Royal College of Surgeons of Edinburgh, UK)
United States

Dr. Izzet Yavuz

MSc, Ph.D., D Ped Dent.
Associate Professor, Pediatric Dentistry Faculty of
Dentistry, University of Dicle Diyarbakir, Turkey

Sanguansak Rerksuppaphol

Department of Pediatrics Faculty of Medicine
Srinakharinwirot University
NakornNayok, Thailand

Dr. William Chi-shing Cho

Ph.D.,
Department of Clinical Oncology
Queen Elizabeth Hospital
Hong Kong

Dr. Michael Wink

Ph.D., Technical University Braunschweig, Germany
Head of Department Institute of Pharmacy and Molecular
Biotechnology, Heidelberg University, Germany

Dr. Pejic Ana

Assistant Medical Faculty Department of Periodontology
and Oral Medicine University of Nis, Serbia

Dr. Ivandro Soares Monteiro

M.Sc., Ph.D. in Psychology Clinic, Professor University of
Minho, Portugal

Dr. Sanjay Dixit, M.D.

Director, EP Laboratories, Philadelphia VA Medical Center
Cardiovascular Medicine - Cardiac Arrhythmia
Univ of Penn School of Medicine
Web: pennmedicine.org/wagform/MainPage.aspx?

Antonio Simone Laganà

M.D. Unit of Gynecology and Obstetrics
Department of Human Pathology in Adulthood and
Childhood "G. Barresi" University of Messina, Italy

Dr. Han-Xiang Deng

MD., Ph.D
Associate Professor and Research Department
Division of Neuromuscular Medicine
Davee Department of Neurology and Clinical
Neurosciences
Northwestern University Feinberg School of Medicine
Web: neurology.northwestern.edu/faculty/deng.html

Dr. Roberto Sanchez

Associate Professor
Department of Structural and Chemical Biology
Mount Sinai School of Medicine
Ph.D., The Rockefeller University
Web: mountsinai.org/

Dr. Feng Feng

Boston University
Microbiology
72 East Concord Street R702
Duke University
United States of America

Dr. Hrushikesh Aphale

MDS- Orthodontics and Dentofacial Orthopedics.
Fellow- World Federation of Orthodontist, USA.

Gaurav Singhal

Master of Tropical Veterinary Sciences, currently
pursuing Ph.D in Medicine

Dr. Pina C. Sanelli

Associate Professor of Radiology
Associate Professor of Public Health
Weill Cornell Medical College
Associate Attending Radiologist
NewYork-Presbyterian Hospital
MRI, MRA, CT, and CTA
Neuroradiology and Diagnostic Radiology
M.D., State University of New York at Buffalo,
School of Medicine and Biomedical Sciences
Web: weillcornell.org/pinasanelli/

Dr. Michael R. Rudnick

M.D., FACP
Associate Professor of Medicine
Chief, Renal Electrolyte and Hypertension Division (PMC)
Penn Medicine, University of Pennsylvania
Presbyterian Medical Center, Philadelphia
Nephrology and Internal Medicine
Certified by the American Board of Internal Medicine
Web: uphs.upenn.edu/

Dr. Seung-Yup Ku

M.D., Ph.D., Seoul National University Medical College,
Seoul, Korea Department of Obstetrics and Gynecology
Seoul National University Hospital, Seoul, Korea

Santhosh Kumar

Reader, Department of Periodontology,
Manipal University, Manipal

Dr. Aarti Garg

Bachelor of Dental Surgery (B.D.S.) M.D.S. in Pedodontics
and Preventive Dentistr Pursuing Phd in Dentistry

Sabreena Safuan

Ph.D (Pathology) MSc (Molecular Pathology and Toxicology) BSc (Biomedicine)

Getahun Asebe

Veterinary medicine, Infectious diseases, Veterinary Public health, Animal Science

Dr. Suraj Agarwal

Bachelor of dental Surgery Master of dental Surgery in Oromaxillofacial Radiology.
Diploma in Forensic Science & Oodontology

Osama Alali

PhD in Orthodontics, Department of Orthodontics, School of Dentistry, University of Damascus. Damascus, Syria. 2013 Masters Degree in Orthodontics.

Prabudh Goel

MCh (Pediatric Surgery, Gold Medalist), FISPU, FICS-IS

Raouf Hajji

MD, Specialty Assistant Professor in Internal Medicine

Surekha Damineni

Ph.D with Post Doctoral in Cancer Genetics

Arundhati Biswas

MBBS, MS (General Surgery), FCPS, MCh, DNB (Neurosurgery)

Rui Pedro Pereira de Almeida

Ph.D Student in Health Sciences program, MSc in Quality Management in Healthcare Facilities

Dr. Sunanda Sharma

B.V.Sc.& AH, M.V.Sc (Animal Reproduction, Obstetrics & gynaecology),
Ph.D.(Animal Reproduction, Obstetrics & gynaecology)

Shahanawaz SD

Master of Physiotherapy in Neurology PhD- Pursuing in Neuro Physiotherapy Master of Physiotherapy in Hospital Management

Dr. Shabana Naz Shah

PhD. in Pharmaceutical Chemistry

Vaishnavi V.K Vedam

Master of dental surgery oral pathology

Tariq Aziz

PhD Biotechnology in Progress

CONTENTS OF THE ISSUE

- i. Copyright Notice
- ii. Editorial Board Members
- iii. Chief Author and Dean
- iv. Contents of the Issue

1. Ultra Sonographic Profile of Nephroblastoma at the University Clinics of Kinshasa. ***1-14***
2. Axillary Nodal Metastases - Prediction by Ultrasound and Digital Mammogram Features of Primary Breast Malignancy. ***15-27***
3. MLC Transmission and Dosimetric Leaf Gap Measurement Using CU Values from Integrated Images of Varian VitalBeam LINAC. ***29-36***
4. Acute Generalized Peritonitis due to Peritoneal Hydatid Cyst Rupture. ***37-40***
5. The Comparison Study of Lung Computerized Tomography Severity Score and Vaccination Status in Covid-19 Patient's. ***41-43***

- v. Fellows
- vi. Auxiliary Memberships
- vii. Preferred Author Guidelines
- viii. Index



GLOBAL JOURNAL OF MEDICAL RESEARCH: D
RADIOLOGY, DIAGNOSTIC AND INSTRUMENTATION
Volume 23 Issue 1 Version 1.0 Year 2023
Type: Double Blind Peer Reviewed International Research Journal
Publisher: Global Journals
Online ISSN: 2249-4618 & Print ISSN: 0975-5888

Ultra Sonographic Profile of Nephroblastoma at the University Clinics of Kinshasa

By Frederick Tshibusu Tshienda, Nadia Cherif Idrissi El Ganouni, Oscar Mokambo Eputa, Nina Domo Nsimba, Aléine Budiongo Nzazi, Karim Assani, Gueth Kundabi Akoto, Damien Kamate Kiraulu, Joseph Bodi Mabilia, Jean René Ngiyulu, Angèle Mbongo Tansia, Gertrude Luyeye Mvita, Jean Mukaya Tshibola, Michel Lelo Tshikwela, Antoine Molua Aundu, François Beya Kabongo, Bienvenu Massamba Lebwaze, Benjamin Kabwe Mwilambwe, Jean Robert Makulo Rissassy, Jean Jacques Malemba, Antoine Tshimpi Wola Yaba, Jean Marie Kayembe Ntumba & Jean Marie Mbuyi Muamba

Cliniques Universitaires de Kinshasa

Abstract- Objective: To describe the ultrasonographic profile of nephroblastoma diagnosed at the university clinics of Kinshasa.

Materials and methods: This is a descriptive study; it concerns 45 patients with Wilms' tumor diagnosed by ultrasonography at the university clinics of Kinshasa from 2016 to 2021, i.e. an overall period of six years. Two ultrasound scanners branded Phillips u-22 and Mindray DC-30 were used.

Keywords: *nephroblastoma, ultrasonography, pediatrics and histopathology.*

GJMR-D Classification: *NLMC Code: QT 34*



Strictly as per the compliance and regulations of:



© 2023. Frederick Tshibusu Tshienda, Nadia Cherif Idrissi El Ganouni, Oscar Mokambo Eputa, Nina Domo Nsimba, Aléine Budiongo Nzazi, Karim Assani, Gueth Kundabi Akoto, Damien Kamate Kiraulu, Joseph Bodi Mabilia, Jean René Ngiyulu, Angèle Mbongo Tansia, Gertrude Luyeye Mvita, Jean Mukaya Tshibola, Michel Lelo Tshikwela, Antoine Molua Aundu, François Beya Kabongo, Bienvenu Massamba Lebwaze, Benjamin Kabwe Mwilambwe, Jean Robert Makulo Rissassy, Jean Jacques Malemba, Antoine Tshimpi Wola Yaba, Jean Marie Kayembe Ntumba & Jean Marie Mbuyi Muamba. This research/review article is distributed under the terms of the Attribution-NonCommercial-NoDerivatives 4.0 International (CC BY-NC-ND 4.0). You must give appropriate credit to authors and reference this article if parts of the article are reproduced in any manner. Applicable licensing terms are at <https://creativecommons.org/licenses/by-nc-nd/4.0/>.

Ultra Sonographic Profile of Nephroblastoma at the University Clinics of Kinshasa

Frederick Tshibusu Tshienda ^α, Nadia Cherif Idrissi El Ganouni ^σ, Oscar Mokambo Eputa ^ρ, Nina Domo Nsimba ^ω, Aléine Budiongo Nzazi [¥], Karim Assani [§], Gueth Kundabi Akoto ^χ, Damien Kamate Kiraulu ^ν, Joseph Bodi Mabilia ^θ, Jean René Ngyulu ^ζ, Angèle Mbongo Tansia [£], Gertrude Luyeye Mvita [€], Jean Mukaya Tshibola ^ƒ, Michel Lelo Tshikwela ^², Antoine Molua Aundu [¢], François Beya Kabongo [^], Bienvenu Massamba Lebwaze ^đ, Benjamin Kabwe Mwilambwe [™], Jean Robert Makulo Rissassy [©], Jean Jacques Malemba [¶], Antoine Tshimpi Wola Yaba ^Ω, Jean Marie Kayembe Ntumba ^ψ & Jean Marie Mbuyi Muamba ^³

Abstract- Objective: To describe the ultrasonographic profile of nephroblastoma diagnosed at the university clinics of Kinshasa.

Materials and methods: This is a descriptive study; it concerns 45 patients with Wilms' tumor diagnosed by ultrasonography at the university clinics of Kinshasa from 2016 to 2021, i.e. an overall period of six years. Two ultrasound scanners branded Phillips u-22 and Mindray DC-30 were used.

Results: We found a male predominance with a sex ratio of 2:1. The median age of the patients was 3 years with extremes ranging from 2 months to 10 years. The clinic was dominated by the palpation of an abdominal mass in 71.1% of cases. The majority of tumors were solid and heterogeneous in 55.2%.

Corresponding Author α: Frederick Tshibusu Tshienda, Service de Radiodiagnostic et Imagerie Médicale, Cliniques Universitaires de Kinshasa, Kinshasa, République Démocratique du Congo. e-mail: fredtshibusu@gmail.com

Author ρ £ € ƒ ² ²: Division of Diagnostic Imaging, University Hospital of Kinshasa, School of Medicine, University of Kinshasa, Kinshasa, Democratic Republic of Congo. e-mail: oscareputamok@gmail.com

Author σ: Department of Medical Imaging, Cadi Ayad University, Faculty of Medicine and Pharmacy, Marrakech, Morocco. e-mails: cherifidrissiganouni@gmail.com, ange_mbongo@yahoo.fr, gluyeye.gl@gmail.com, mtj@perso.be, lelocare60@gmail.com, aamolua@yahoo.fr

Author ω ¥ § χ θ ζ: Department of pediatrics, Kinshasa University Hospital, School of Medicine, University of Kinshasa, Kinshasa, Democratic Republic of Congo. e-mails: domonina23@gmail.com, albudiongo@gmail.com, guethkundabi84@gmail.com, drassanik@gmail.com, josephbodi9@gmail.com, relyse2000@yahoo.fr

Author ν: Department of Surgery, Division of Pediatrics, Kinshasa University Hospital, School of Medicine, University of Kinshasa, Democratic Republic of the Congo. e-mail: kkirauli@yahoo.com

Author ^ đ: Department of Anatomopathology, Kinshasa University Hospital, School of Medicine, University of Kinshasa, Kinshasa, Democratic Republic of Congo. e-mails: beyafranklin@yahoo.fr, bienvenulebwaze@gmail.com

Author ™ ©: Department of Anesthesia and Intensive Care, Kinshasa University Hospital, School of Medicine, University of Kinshasa, Kinshasa, Democratic Republic of Congo. e-mails: benjamin.kabwe@unikin.ac.cd, jrmakulo2016@gmail.com

Author ¶ Ω Ψ ³: Department of internalmedicine, Kinshasa University Hospital, School of Medicine, University of Kinshasa, Kinshasa, Democratic Republic of Congo. e-mails: antshimpi@aol.com, jm.kayembe@unikin.ac.cd, MbuyiMuamba@yahoo.fr, jeje_malemba2003@hotmail.com

The left renal location was predominant in 51.2% of cases. Ultrasonography was the imaging modality used for diagnosis and follow-up after chemotherapy and surgery. Stages I and III were predominant in 78.6% of cases, mixed type nephroblastoma represented 55.1% of cases and intermediate risk tumors 85.7% of cases.

Conclusion: The ultrasonographic profile of nephroblastoma at CUK was more revealed by an abdominal mass [71.1%], found in patients aged 2 to 240 months with a male predominance. The most predominant sonographic appearance was that of a solid, heterogeneous tumor [55.2%] and the left renal localization was the most prevalent [51.2%]. Stages I and III were predominant [78.6%] of cases. Mixed type nephroblastoma represented 55.1% of cases and intermediate risk tumors 85.7% of cases. These findings corroborate mostly the data of the literature.

Keywords: nephroblastoma, ultrasonography, pediatrics and histopathology.

I. INTRODUCTION

Nephroblastoma, or Wilms' tumor, is a renal tumor occurring predominantly in children. It accounts for more than 90% of malignant renal tumors in children and mainly affects children under 5 years of age [1-3]. Nephroblastoma is very different from adult kidney cancer, as it is an embryonic tumor, developing from the metanephros, whose differentiation and proliferation give rise to the kidney [3]. In most Western populations, nephroblastoma accounts for up to 6% of all cancers diagnosed in children. In black populations in North America and Africa, the proportion is about 10% [4]. It is rarely found in adults [5, 6]. In sub-Saharan Africa, nephroblastoma is among the five diseases that account for 70% of childhood cancers [7]. Although Wilms' tumor is often curable in developed countries, affected children in middle-income countries experience poor outcomes. ABDALLAH FK et al in 2001 in an analysis of survival of nephroblastoma in Kenyan patients reported a two-year event-free survival (EFS) of 34.7% which contrasts with the survival rate of over 90% at 5 years in developed countries. However, thanks to the Franco-African Pediatric Oncology Group

(FAOPG), a protocol adapted to the African context where patients are seen late with large abdominal masses has significantly improved the prognosis in French-speaking Africa [7, 9]. Ultrasonography, plays a key role in the management of Wilms' tumor, as the decision to initiate preoperative chemotherapy is made without pathological evidence, according to the 2001 International Society of Pediatric Oncology (ISOP) protocol [2, 10]. Nephroblastoma represents the third most common pediatric cancer (15%) after non-Hodgkin's malignant lymphoma and retinoblastoma according to the study carried out by ABDOUL KD et al in the Bamako pediatric oncology unit [9] in Mali. In the Democratic Republic of Congo (DRC), studies by MPUTU [11], LUNTALA [12], KONGOLO [13], PALANGI [14] and KAZADI [15] in the eighties and nineties had demonstrated that this serious pathology was frequent in our setting and posed a real problem of early diagnosis. A literature review of cases in the pediatric hemato-oncology unit of the CUK had reported between 2000 and 2018 a rate of 13% of cases of nephroblastoma, placing it in 4th position after retinoblastoma, lymphomas and leukemias [16]. Although some studies evaluating the frequency of nephroblastoma on the basis of conventional radiology data have already been carried out [10], no study to date has evaluated the contribution of ultrasonography in the management of nephroblastoma in the hospital setting of Kinshasa; hence the interest of the present study, whose mission is to describe the ultrasonographic profile of nephroblastoma in the university clinics of Kinshasa.

II. MATERIALS AND METHODS

Type and period of the study: This was a descriptive documentary study of nephroblastoma cases diagnosed in the medical imaging department of the CUK during a period of six years from January 2016 to January 2021. Study population: this study included 45 patients, aged from 1.5 months to 10 years with a median age of 3.0 with extremes (2.0-4.0) years. Thirty patients were male and 15 females. Inclusion criteria: Any patient referred for suspicion of an abdominal mass with a lumbar contact; any patient who had undergone a renal Doppler ultrasound scan; and any patient with a complete medical record. Non-inclusion criteria: The following patients were not included in this study: patients who did not perform a renal Doppler ultrasound, patients who did not perform histopathological analysis after surgery, and patients with incomplete medical records. In relation to the parameters of interest and operational definitions we noted: a) Socio-demographic parameters: including age and sex of the patients; b) Clinical parameters: including sensation of an abdominal mass with lumbar contact on palpation, hematuria, abdominal pain, altered general

condition, digestive disorder and notion of abdominal trauma; c) Biological parameters: hemoglobin, urea and creatinine; d) Ultrasonographic parameters: b.1) tumor location: right unilateral, left unilateral or bilateral; b.2) the renal take-off point: (upper pole, lower pole, medio renal, toto renal); b.3) the tumor volume, obtained by automatic multiplication of the height (h) times width (l) times thickness (e) with a conversion factor of 0.523 ($h \times l \times e \times 0.523$); the product is expressed in cm^3 or ml; b.4) the echostructure: which can be used to determine the size of the tumor; b.5) the size of the tumor: ($h \times l \times e \times 0.523$) the echostructure: which can be solid, mixed (solid-cystic) and or cystic; b.5) the necrotic-cystic zones: defined by the presence of empty patches of echoes within the tumor mass, b.5) the presence or absence of the tumor capsule: defined by a thin layer separating the b.6) Tumor echogenicity: defined by the brightness or not of the tumor in relation to the surrounding structures, which may be hypoechoic, hyperechoic or isoechoic; b.7) Spur sign: defined by the extension of the healthy renal parenchyma progressively connecting to the renal mass (fig.11), b.8) Contours: defined by the limits of the tumor and can be regular or irregular; b.9) Tumor rupture: defined by the presence of a perirenal or peri-tumoral collection, b.10) Calcifications: defined by the presence of intra-tumoral hyperechoic images with or without posterior shadow cone, b.11) displacement of the pyelocal cavities and/or vessels: defined by the displacement of intra-abdominal organs adjacent to the tumor, b.12) compensatory hypertrophy of the contralateral kidney: defined by an increase in size of the breast kidney, b.13) tumor vascularization (fig.12), b.14) loco-regional tumor extension: defined by the invasion of loco-regional structures by the tumor; the latter may be: the renal vein and or the inferior vena cava by a thrombosis (fig.12), the transmedian extension; defined by the overtaking of the median line by the tumor, the latter defined by the linea alba, the intraperitoneal effusion by an attack on peritoneal, the satellite nodule on the homolateral or contralateral kidney, adenomegaly (fig.13), and finally hepatic nodules. e) The anatomopathological parameters sought were: e.1) the histological type of the tumour: (mixed, stromal, epithelial and blastematos), e.2) risk and stage according to the 2001 SIOP classification, and e.3) grouping of four stages into two main groups: stages I and II: considered as tumors with complete resection and stages III and IV considered as tumors with incomplete resection according to the ultrasonographic characteristics. As for data processing and statistical analysis, it should be noted that the data were collected on a collection form encoded using Excel 2013 software. After verification and cleaning of the database, they were exported to SPSS for Windows version 24 for analysis. Categorical variables were presented as absolute and relative frequencies (%), quantitative variables were summarized by measures of

central tendency and dispersion. The mean and its standard deviation were reported for data with a Gaussian distribution; however, those that did not follow the Gaussian distribution were summarized as median and interquartile range (IQR). Pearson's chi-square or Fischer's exact test was used to compare proportions; Student's t-test compared means; and Mann Whitney U-test compared medians. For all tests used, the p value < 0.05 was the threshold of statistical significance.

III. RESULTS

In relation to sociodemographic parameters; the median age in the present study was three years with the extremes ranging from two months to ten years [Figure 1]. The majority of patients were between two and four years of age (44.4%) [Figure 1]. The majority of patients were male (66.7%) with a sex ratio of 2:1 [Figure 2]. Median urea and creatinine values were 20.8 (13.4-27.1) mg/dl for urea and 0.60 (0.45-0.70) mg/dl for creatinine. The overall mean hemoglobin value was 8.5 ± 1.9 g/dl [Table 1]. Ultrasonography, was used in forty-five patients, or 100.0%. We noted twenty-two tumors in the left kidney, or 48.88%, nineteen tumors in the right kidney, or 42.22%, and bilateral localization in two patients, or 4.44% [table 2]. The majority of tumors presented a solid, heterogeneous echostructure in twenty-four patients, i.e. 53.33%; solid tumors with necrotic-cystic patches were present in nineteen patients, i.e. 42.22% [Table 2]. In relation to flight points: nineteen tumors were upper polar or 42.22%, eleven lower polar tumors or 24.44%, one mid-polar tumor or 2.22% and twelve total renal tumors or 26.66% [Table 2]. The median value of tumor volume was 985 (665-1196) ml with the extremes ranging from 100 ml to 6127ml. Spur sign was found in twelve patients or 26.66%. The tumor contours were irregular in thirty patients or 66.66% and regular in thirteen patients or 28.88% [Table 2]. The tumor capsule was intact in eighteen patients, or 17.77%, while tumor rupture was found in three patients, or 6.66% [Table 2]. The pyelocalic cavities were repressed in four patients, or 8.88% [Table 2]. In relation to tumor echogenicity, there were twenty-three hypoechoic tumors, or 51.11% [Table 2]. In boys, twelve patients or 42.9% had hypoechoic tumors, whereas in girls eleven patients or 73.33% had hypoechoic tumors [Table 1-2]. Hyperechoic tumors were found in twelve patients, i.e. 26.66%; in boys nine patients, i.e. 32.1% and in girls three patients, i.e. 20% and iso echogenic tumors in eight patients of which seven boys and one girl. We found intra-tumor calcifications in nine patients, or 20% [Table 2]. Compensatory hypertrophy of the contralateral kidney was found in four patients, i.e., 8.88%, and tumor vascularization was well objectified in seventeen patients, i.e., 37.77% [Table 2]. The inventory of the parameters of locoregional tumor extension on ultrasonography reveals the following; reflow without

invasion of neighboring structures was found in seventeen patients, i.e., 37.77%; adenomegaly was found in thirteen patients, i.e., 28.88% [Table 2]. Venous thrombus was found in twelve patients, i.e. 26.66%, in five patients, i.e. 11.11%, the thrombus was located within the renal vein and in seven patients, i.e. 15.55%, the thrombus was located within the inferior vena cava [Table 2]. In seven patients (15.55%), we found a transmedian extension [Table 2]. Peritoneal fluid effusion was found in five patients (11.11%) and liver metastases in three patients (6.66%). The whole group had a median tumor volume of 560.6 (313.9- 843.4) ml [Table 2]. On the anatomopathological level twenty-nine patients, or 64.4% had benefited from a histopathological examination after enlarged total uretero-nephrectomy, among which we note seventeen boys or 58.62% and twelve girls or 26.66% [table 5]. According to the histological types, sixteen patients, i.e. 55.17%, presented the mixed type; the stromal and regressive types were found in 3 patients, i.e. 10.34% each; the blastomatous and epithelial types were found in 2 patients each, i.e. 6.89% [Table 5]. We also found one case of partially differentiated cystic nephroblastoma (3.44%) [Table 5]. According to the tumor stage, stages I and III were in the majority, representing 39.3% each; while stage II represented 17.9% and stage IV 3.6% [Figure 3]. We noted 85.7% of tumors of intermediate risk against 7.1% of low and high-risk tumors in the same proportions [Figure 4].

IV. DISCUSSION

In our series, the median age in the study population was 36 months with the extremes ranging from 2 months to 120 months. The majority of patients were between 2 and 4 years of age, representing 44.4% of cases. Diakit  F et al [17] and Atanda AT et al [18] respectively in Guinea (2012) and Nigeria (2015) had found a mean age of about 5 years. Age extremes ranging from 13 to 130 months in the study of Diakit  et al [17]. This difference could be explained by the improved management with the support of GFAOP. Molua, in his final thesis, found extremes of age from 12 to 60 months [1]. This statement is consistent with our observation and those of several authors [2,9,10,19]. In the present study, the male sex was the most affected with a sex ratio of 2/1. Kant  A. et al [20] had noted a slight female predominance. Our observation is similar to those of Atanda AT et al [18] and Diakit  F. et al [17]; however, no statistically significant association has been demonstrated. In our series, the clinical signs were dominated by the discovery of abdominal distension (71.1%), followed by general signs (44.4%), abdominal mass with lumbar contact (35.6%), abdominal pain (31.1%), hematuria (24.4%), constipation (2.2%) and trauma (2.2%). These results are consistent with those of Bouzahir AM et al [21]. according to data from the

National Cancer Institute in the USA [21]: asymptomatic abdominal distension: is the most frequent clinical presentation found in children during bathing or dressing. Abdominal pain is seen in 40% of cases; macroscopic hematuria in 18%, microscopic hematuria in 24% and hypertension present in almost 25% of patients at the time of discovery of nephroblastoma. The latter is secondary to activation of the renin-angiotensin-aldosterone system. Symptoms of alteration of the general state, namely: anorexia, weight loss and fever may occur in less than 10% of cases. Other manifestations related to complications may also be indicative of nephroblastoma, including vascular obstruction, distant metastases that may be pulmonary or hepatic, pulmonary embolism, collateral venous circulation, and varicocele due to obstruction of the inferior vena cava. Renal function studied by urea and plasma creatinine was normal in our study. This could be explained by the unilaterality of the renal involvement. Indeed, in case of unilateral damage, we think that the remaining healthy renal parenchyma could contribute to the preservation of the function. These data agree with those of Molua [1] and those of the literature. Our study did not find any association with congenital malformations or genetic predisposition syndromes to nephroblastoma. This could be explained by the absence of genetic testing in patients with nephroblastoma in our series. In our series, abdominopelvic Doppler ultrasound was performed in 100.0% of patients. It found a right renal location in 19 patients (42.22%), a left renal location in 22 patients (48.88%), i.e. a unilateral involvement of 91.10%, and a bilateral involvement in four patients, i.e. 8.89%. Bouzahir MA et al [21] note that abdominal ultrasound performed in all patients (100% of cases) showed a slight predominance of right renal tumors, i.e. 50% and left renal tumors 46.7% of cases; while bilateral involvement 3.3% of cases. Our observations are similar to those of Diakit  F. et al [17]. In our study, the majority of tumors had a solid and heterogeneous echostructure in 55.8% of patients. In some previous studies (LAIGLE V. et al in Nantes in 2011), tumor heterogeneity on ultrasonography represented a discriminating feature, nephroblastoma being more heterogeneous than other renal tumors; however, this feature remains at the limit of significance ($p=0.05$) and this was not confirmed on ultrasonography. In relation to the flight point in the present series, 19 cases (44.2%) were superior polar, 11 cases (25.6%) inferior polar, i.e. a frequency of 69.8% of polar development, 1 case (2.3%) medial-renal and 12 cases (27.9%) occupied the entire renal parenchyma. According to the literature, nephroblastoma usually develops at one renal pole but can also be multifocal, disorganizing and displacing normal anatomical elements of the kidney [23,24]. In the present study, the spur sign accounted for 27.9% (12cases). Zrig A. et al [25] in Tunisia in 2014 had found the spur sign in 45

patients out of 113 observations or 39.8%. This low rate can be attributed to the large tumor volume at tumor discovery in our series. In most cases, the mass is well limited [23]. In our series, we found masses with irregular contours in 69.8%. This high rate of irregularity of the contours could be justified by the initial ultrasound performed at an advanced stage of the tumor. The mass may appear encapsulated [23], in our series we found 41.9% (18 cases) of encapsulated tumor and this could be related to the local stage of the mass (stage I and II and III) which is determined after nephrectomy and histopathological analysis. Most of the tumors were hypoechoic in 53.5% (23 cases), hyperechoic tumors in 27.9% (12 cases) and iso echogenic in 18.6% (8 cases); hypoechoic masses were more noticed in girls, hyper and iso echogenic more noticed in boys with a significant statistical analysis ($p=0.037$) However, this data is subject to the small sample size of our study, thus opening up a boulevard for future research that may confirm or refute this hypothesis. Calcifications are possible in renal tumors but not very frequent. They are associated with the corbelling sign, invasion of the medullary canal and forward displacement of the aorta; thus posing a problem of differential diagnosis with neuroblastoma [2]. In our series, we found nine lesions with calcifications (20.9%), thus arguing in favor of an advanced stage tumor (III or IV); with possibility of incomplete resection at surgery and significant statistical analysis ($p=0.001$). In relation to locoregional extension: venous thrombosis is classically described as a sign pointing to a nephroblastoma. In our series, we found 12 patients with venous thrombosis, i.e. 26.66%; among them, 5 patients, i.e. 41.66%, had benefited from a histopathological analysis after nephrectomy, the diagnosis of nephroblastoma was confirmed. LAIGLE et al [2] found 4 cases of nephroblastoma, two of tumors were non-nephroblastoma, 6 cases (10%) out of 60 and the 2 cases were false negative on ultrasound and thrombosis present on CT. The high rate of venous thrombosis in this study could be justified by the late discovery of the tumor on the one hand and by the ability of the radiologist to look for it before any case of nephroblastoma on the other. According to the literature [2], it is known that large nodes can be found in reaction to the tumor, without tumor invasion. Their presence may be responsible for false positive lymph node metastases. During the operation, the surgeon has no intraoperative morphological criteria to differentiate metastatic adenopathy from reactionary adenopathy. Only histological data can be used to determine this difference, which is why the SIOP recommends systematic lymph node biopsies. However, their absence could be reassuring as to the lymph node status. In our series, we found thirteen patients (28.88%) with adenomegaly of which ten patients had undergone nephrectomy and histopathological analysis which showed six patients with completely resected tumors

(i.e. stage I and II) and four patients with incompletely resected tumors (i.e. stage III and IV) and the difference was statistically insignificant ($p=0.609$), justifying that any adenomegaly would not mean tumor invasion. In our series, we found patients with metastasis in 17.7% or eight patients. Metastases were localized only to the lungs in five patients and to the liver in two patients. The simultaneous localization of the liver and lung in one patient, i.e. a hepatic localization in 37.5% of the metastatic patients, this high rate of liver metastases could be justified by the late discovery of the tumor. In the literature, liver metastases are much rarer [10]. KADRI N. et al in Morocco in 2021 [37], found three patients with liver metastases out of thirteen metastatic patients, i.e. a proportion of 23%. These three cases had simultaneous metastases in the lung. MOULOT MO et al [19] in Ivory Coast 2018 had found metastatic cases in 18.6% ($n = 10$). Chest X-ray was performed in all patients i.e. 100% to look for lung metastasis. In this study 64.4% ($n=29$) of patients had undergone histological analysis after extended nephrectomy. All patients had benefited from histology in the studies conducted by LAIGLE V and MOLUA [1,2]. This low rate of histology in our series could be explained by the lack of financial means for some parents, the absence of surgery for some patients, the non-availability of the histological report in the patient's file and death before a possible nephrectomy. However, this cohort remains representative with figures usually described, with a clear predominance of nephroblastoma, representing 93.1% (27 cases) in this series, the figures in the literature range from 87 to 93% [1,2,10,23]. In our study, a large majority of patients presented with intermediate risk tumors at 85.7%, whereas FOFANA N.S et al [22] found 62.5% of high-risk tumors. This difference could be explained by the fact that in the latter study only metastatic nephroblastoma's are concerned. Our study is similar to that of BOUZHIR M. A et al [21] and KADRI N. et al [26] who noted a predominance of tumors of intermediate risk respectively of 83.3% and 45%. Concerning the ultrasonographic characteristics of the renal tumors according to the clinico-pathological stage; the right location, the regular tumor contours and the spur sign were more associated with tumors with complete resection, whereas the left location, the irregular contours as well as the intra-tumoral calcifications were associated with tumors with incomplete resection with statistically significant analyses for laterality ($p=0.021$), contours ($p=0.014$), calcifications ($p=0.001$). The spur sign did not show a statistically significant analysis ($p=0.132$) but there were eight cases or 50% of completely resected tumors versus 2 cases or 20% of incompletely resected tumors. Elements such as reflow without invasion of neighboring structures and pleural effusion pleaded in favour of an incompletely resected tumour but were not statistically significant ($p=0.092$ and $p=0.142$). However, these

results are taken with reservation, and we hope to carry out a study with a larger sample to confirm or refute these data. Regarding the limitations of this study, it should be noted that its retrospective nature, the lack of systematic histopathological analysis in all patients, the low rate of CT scan and the lack of nephrectomy in some patients were the main limitations of this study. As strengths: the present series, is a first study performed in our setting and having used cross-sectional imaging (US and CT).

V. CONCLUSION

This study, which aimed to establish the ultrasonographic profile of nephroblastoma at the university clinics of Kinshasa, allowed us to make the following observations: children under 5 years of age, predominantly male, with a median age of three years, were referred for abdominal bloating, moderate anemia with disturbance of renal function; in whom abdominal palpation revealed an abdominal mass with positive lumbar contact. The ultrasonography performed in all patients with good histopathological correlation showed the following characteristics a predominance of the left renal localization, of a solid, hypoechoic, heterogeneous tumor, with a median tumor volume of 560.6 (313.9-843.4) ml, dotted with necrotic-cystic patches, with as the most frequent upper polar take-off point, a less frequent spur sign, tumor contours frequently irregular in more than half of the patients, less frequent capsular rupture, less frequent compensatory hypertrophy of the contralateral kidney, less frequent intra-tumor vascularization, frequent repression of neighboring organs; Thrombotic impregnation was found in a quarter of patients; peritoneal fluid effusion, adenomegaly and liver metastases were less frequent. On the anatomopathological level, the mixed type was the most frequently encountered, followed by the stromal and regressive types; stages I and III were in the majority and nearly 90% of patients represented the intermediate risk. In view of the above, ultrasonography represents the imaging means adapted to the socio-economic conditions of our population for the initial diagnosis, the assessment of locoregional and distant extension without forgetting the follow-up of the children having benefited from chemotherapy and surgery.

VI. PROTECTION OF HUMAN AND ANIMAL

Rights The authors declare that this study did not involve experiments on patients, subjects, or animals. Confidentiality of Data: The authors declare that this study does not contain any personal data that could identify the patient or subject. Funding of the Study This study did not receive specific funding from any public or private institution.

Funding of the Study: This study did not receive specific funding from any public or private institution.

Conflict of Interest Statement: All the authors do not have any possible conflicts of interest.

Contribution and Responsibility of the Authors: 1. Dr. Frederick Tshibas Tshienda: writing and proofreading.

2. Oscar Mokambo Eputa: writing and proofreading, 3. René Ngyulu Makwala: Proofreading. 4. Nadia Cherif Idrissi El Ganouni: proofreading, 5. Jean Mukaya Tshibola: proofreading.

Table 1: Distribution of patients according to clinical and biological parameters

Parameters	Whole group n=45	Male n=30	Female n=15	P
Abdominal distension	32(71,1)	22(73,3)	10(66,7)	0,447
Palpated abdominal mass	16(35,6)	11(36,7)	5(33,3)	0,548
Hematuria	11(24,4)	6(20,0)	5(33,3)	0,266
Abdominal pain	14(31,1)	9(30,0)	5(33,3)	0,539
General signs	20(44,4)	14(46,7)	6(40,0)	0,460
Digestive disorder	1(2,2)	0(0,0)	1(6,7)	-
Notion of trauma	1(2,2)	1(3,3)	0(0,0)	-
Urea (mg/dl)	20,8(13,4-27,1)	20,5(11,9-29,3)	21,0(10,2-28,0)	0,664
Créatinine(mg/dl)	0,60(0,45-0,70)	0,59(0,40-0,70)	0,60(0,40-0,70)	0,311
Hb(g/dl)	8,5±1,9	8,8±1,9	8,9±2,0	0,879

Table 2: Ultrasonographic characteristics according to clinicopathological stages and tumor extension according to stage

Variables	Total resection tumor n=16	Incompletely resected tumor n=10	P
o Clinical-pathological stages			
Tumor location			0,021
Right kidney	11(68,8)	2(20,0)	
Left kidney	5(31,3)	8(80,0)	
Echostructure			0,412
Solid	10(62,5)	5(50,0)	
Mixed	6(37,5)	5(50,0)	
Flight point			0,503
Superior pole	9(56,3)	4(40,0)	
Lower pole	5(31,3)	3(30,0)	
kidney toto	2(12,5)	3(20,0)	
Spur sign	8(50,0)	2(20,0)	0,132
Contours			0,014
Irregular	7(43,8)	7(70,0)	
Regular	9(56,3)	3(30,0)	
Presence of the tumor capsule	8(50,0)	5(50,0)	0,656
Tumor rupture (suspicion)	0(0,0)	1(10,0)	

PC cavitydischarge	0(0,0)	1(10,0)	
Echogenicity			0,266
Hypoechoogenic	11(68,8)	7(70,0)	
Hyperechoogenic	2(12,5)	3(30,0)	
Isoechoogenic	3(18,8)	0(0,0)	
Necrosis	9(56,3)	6(60,0)	0,588
Hemorrhage	2(12,5)	0(0,0)	
Calcifications	1(6,9)	7(70,0)	0,001
Hypertrophy compensatory	1(6,3)	2(20,0)	0,323
Vascularization	6(37,5)	3(30,0)	0,517
o Tumor extension according to stage			
Transmedian extension	2(12,5)	3(30,0)	0,274
Repression without invasion	6(37,5)	7(70,0)	0,092
Intraperitoneal effusion	1(6,3)	3(30,0)	0,142
Satellitenodule	0(0,0)	1(10,0)	
Presence of thrombus	4(25,0)	1(10,0)	0,343
Renalvein	2(12,5)	1(10,0)	0,677
inferior vena cava	2(12,5)	1(10,0)	0,677
Proximal segment	0(0,0)	1(10,0)	-
Presence of adenomegaly	6(37,5)	4(40,0)	0,609
Hepaticmetastasis	0(0,0)	2(20,0)	-

Table 3: Distribution of patients according to parameters of locoregional tumor extension on ultrasonography

Variables	Actual number	Percentage
o Histological type of tumors		
Mixed type nephroblastoma	16	55,2
Nephroblastoma, stromal type	3	10,3
Nephroblastoma, régressive type	3	10,3
Nephroblastoma blastematous type	2	-
Nephroblastoma epithelial type	2	-
Inflammatory mass	1	-
Partially cystic differentiated nephroblastoma	1	-
Mesoblasticnephroma	1	-
Total	29	100,0
o Tumor risk		
Intermediate Risk		85,8
High risk		7,1
Low risk		7,1
Total		100

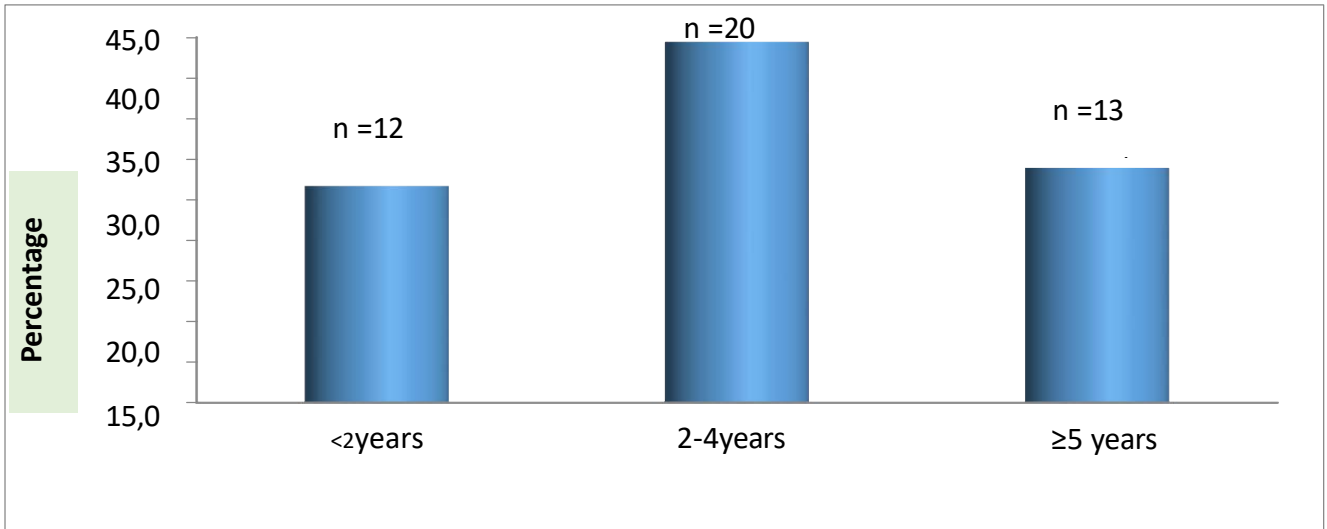


Figure 1: Distribution of children according to age.

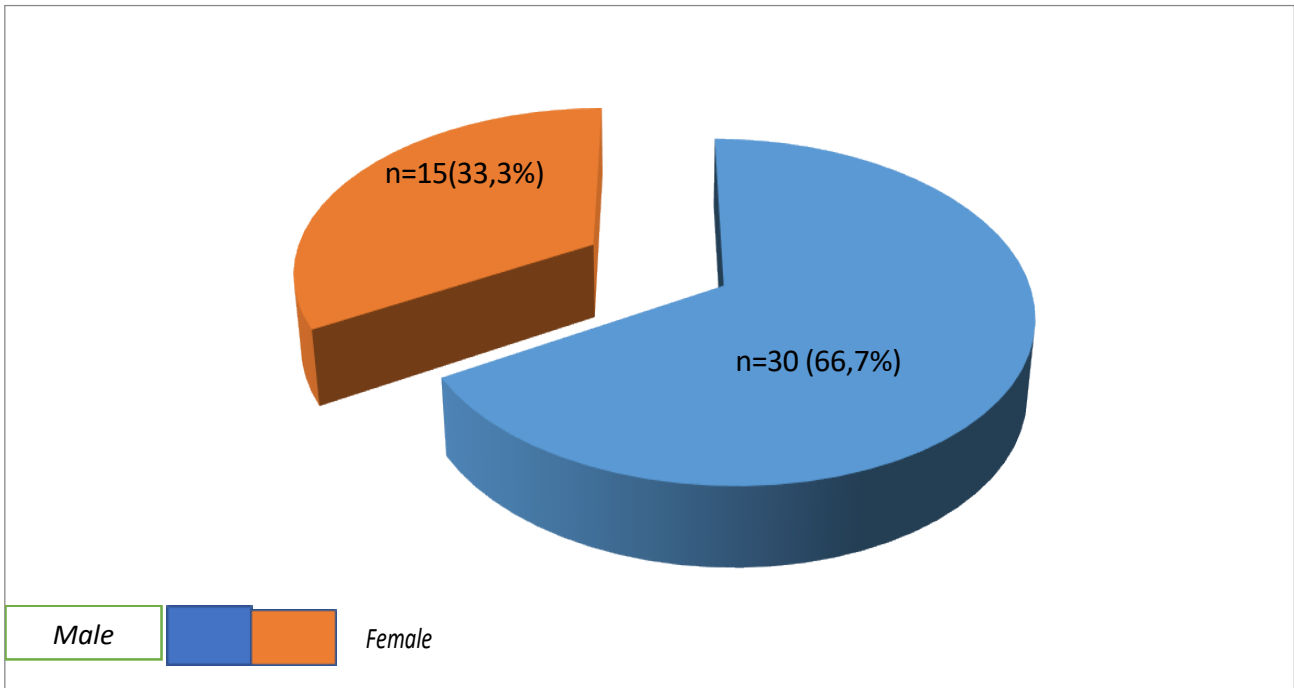


Figure 2: Distribution of children by sex.

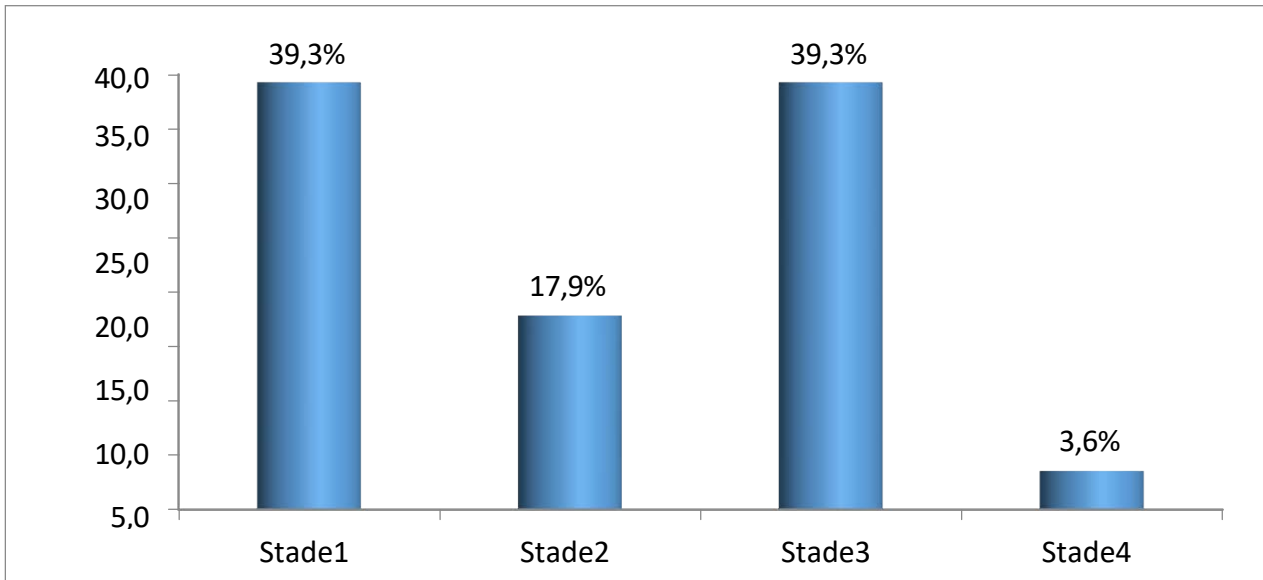


Figure 3: Distribution according to tumor stage.

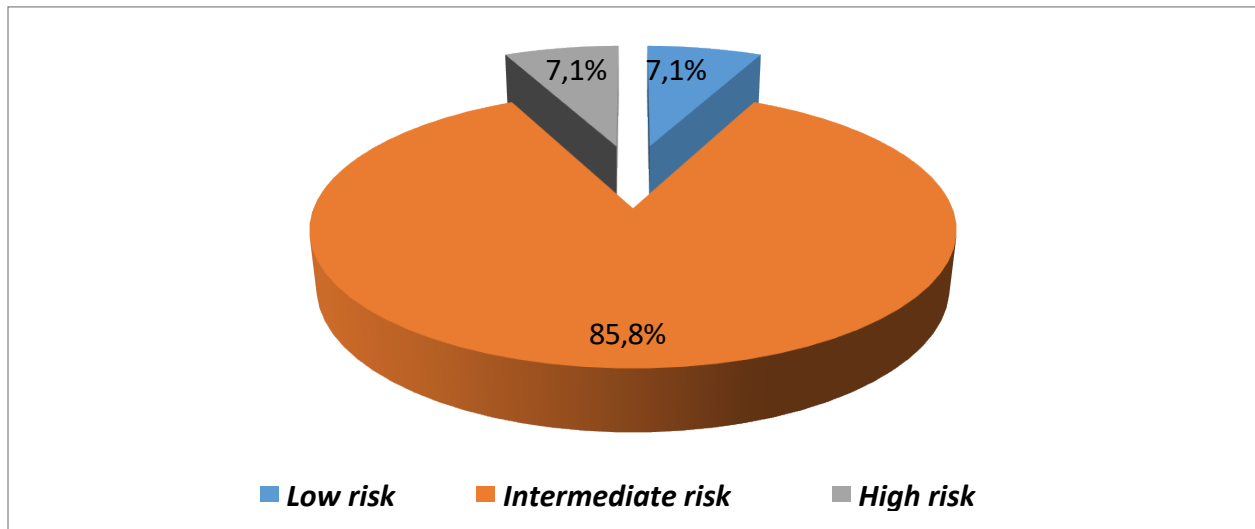


Figure 4: Distribution by tumor risk.



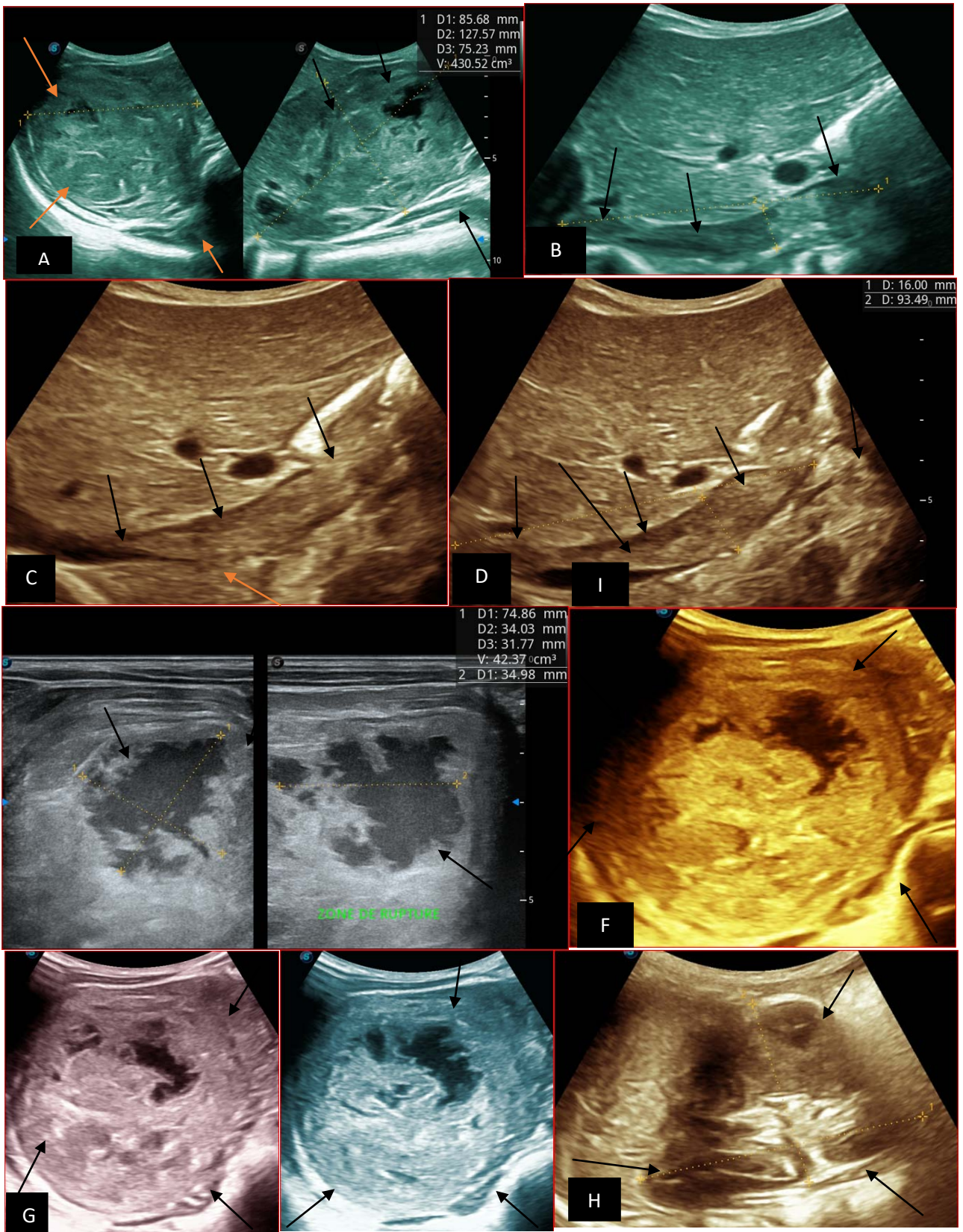


Figure 5: Abdominopelvic ultrasound control after 6 courses of chemotherapy in the same 3 year old patient with a ruptured left renal nephroblastoma; Images A, F, G, and H: show regression of the solid, endo and exo renal, left nephroblastoma mass treated with 6 courses of chemotherapy (current volume 430 ml vs) Images: B, C, and: show persistence of thrombotic permeation pan vena cava and ipsilateral renal. Image E: shows a volumetric regression of the intra-lesional hematic collection, at the tumor rupture estimated at 34.49 ml VS, Image I: represents the right kidney in B mode which is of normal echostructure. Source : Dr. Frederick Tshibusu Tshienda database.

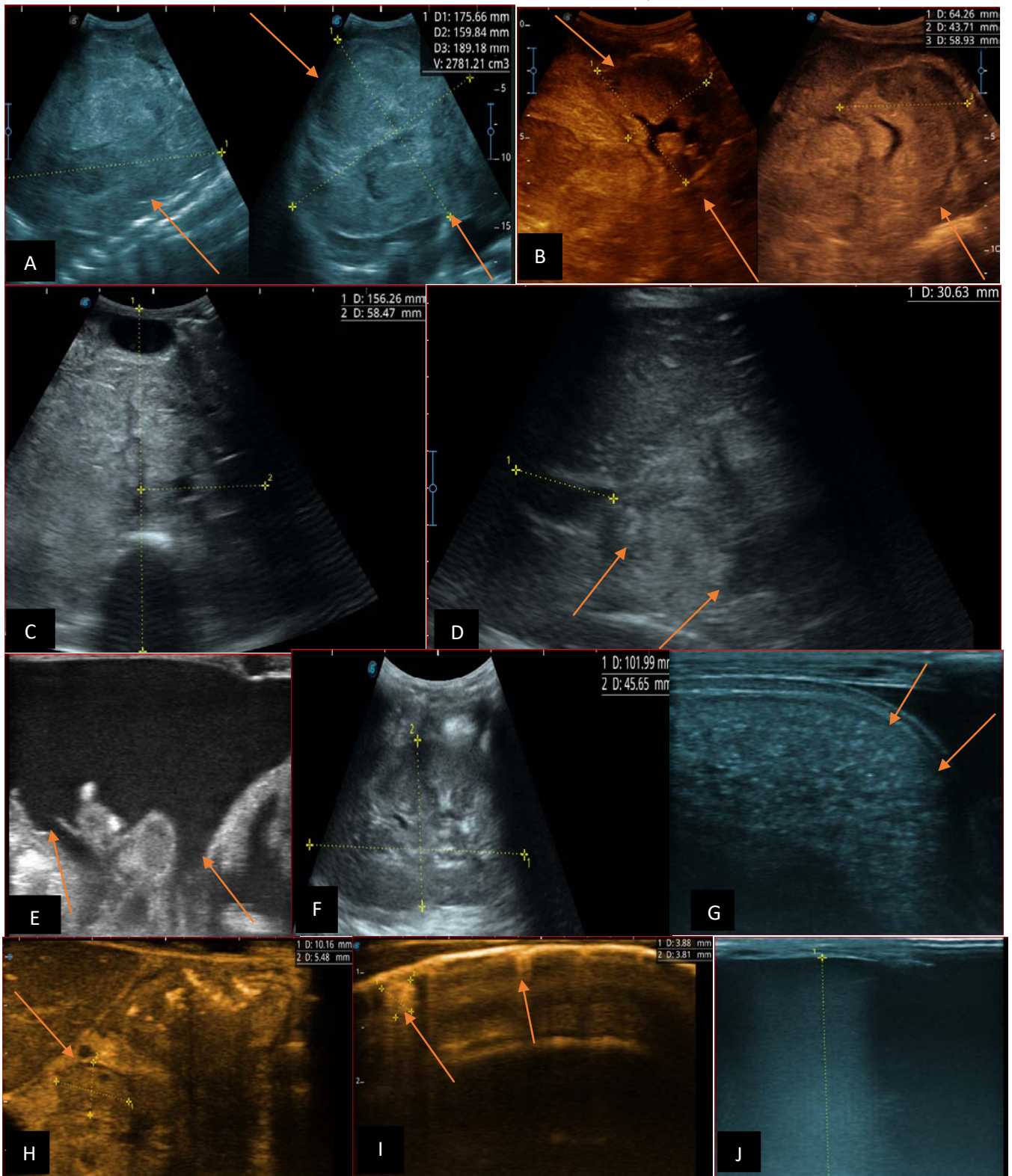


Figure 6: 9-year-old sickle cell patient, referred for abdominal bloating with significant collateral venous circulation, in whom we noted: Image A: mass, Image B: healthy renal stump, inferior polar; Image C: left transmedian extension, Image D: thrombosis of the vena cava segments: supra, retro and sub hepatic, sparing a part of the supra hepatic vena cava segment over 30 mm. Image: Ascites of great abundance, Image F: normal left kidney, Image G: splenic microcalcifications, Image H: celiac adenopathy, Image I: sub pleural pulmonary nodules with the biggest measuring 3.88x3.81 mm, Image j: left pleurisy of great abundance. Source: Dr. Frederick Tshibusu Tshienda database.

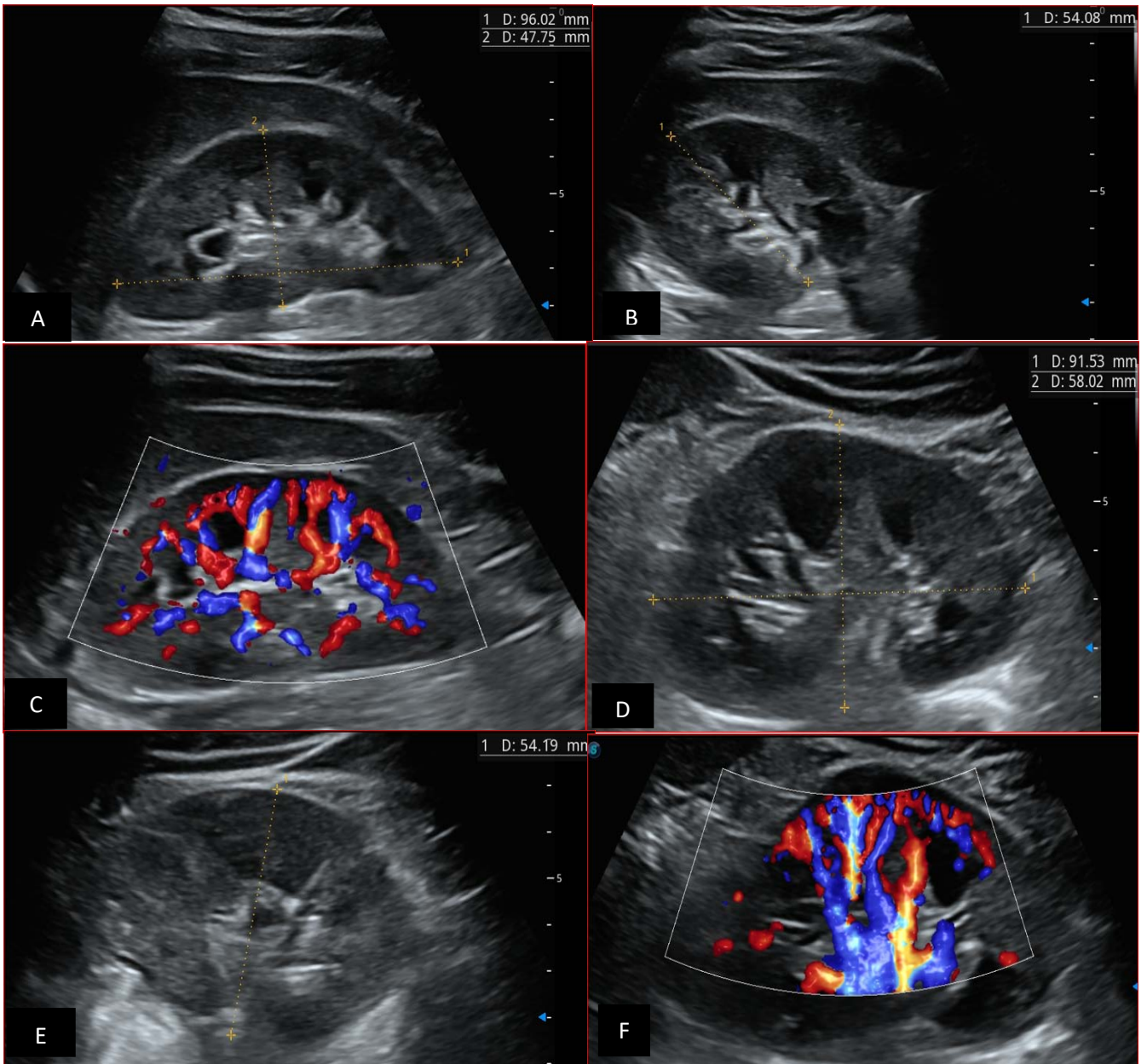


Figure 7: 7-year-old patient with normal renal Doppler ultrasound examination: Images A and B: normal morphology of the right kidney in B-mode; Image C: normal vascularization of the right kidney in color Doppler mode. Images C and D: represent a normal morphology of the left kidney in B mode. Image F: represents normal vascularization of the left kidney in color Doppler mode. Source : Dr. Frederick Tshibusu Tshienda database.

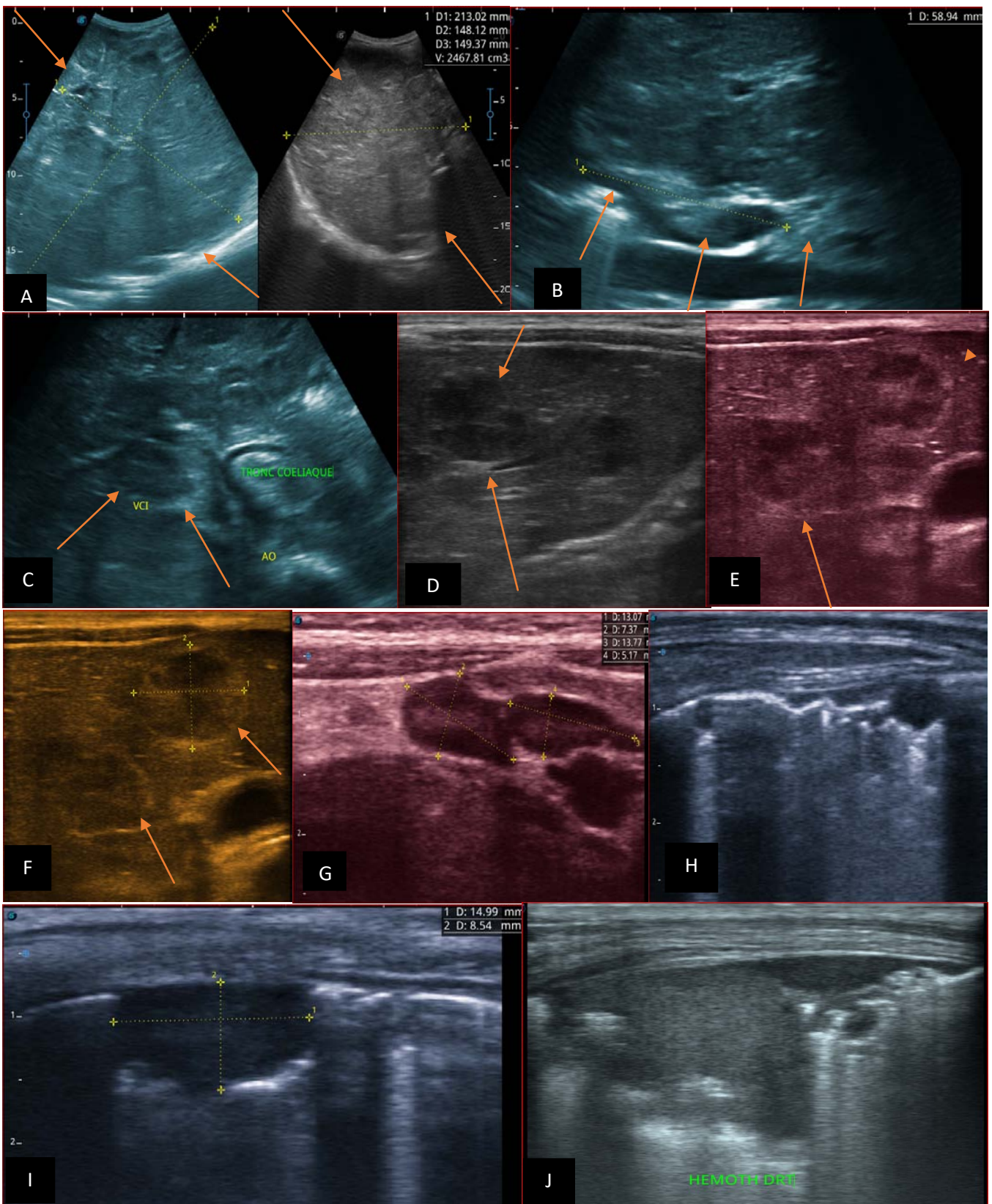


Figure 8: Patient aged 6 years, referred for abdominal bloating, in whom we noted: Image A: illustrates a right endo and exo renal solid mass, in B mode, heterogeneous, interspersed with hypo, iso and hyperechoic areas. Images B and C: illustrate an echogenic thrombotic impregnation of the inferior vena cava. Images D-E-F: in B mode, illustrate pan-hepatic nodular lesions related to liver metastases Image G: in B mode illustrates hypoechoic coelio-mesenteric adenopathies. Images H-I: illustrates sub pleural lung parenchymal nodules in relation to lung metastases. Image J: in B mode, illustrating an echogenic pulmonary effusion, related to a hemothorax

REFERENCES RÉFÉRENCES REFERENCIAS

1. Molua A. Contribution of radiology in the diagnosis of nephroblastoma. 1996.
2. Laigle V, Querat. CT scan of renal tumors in children managed according to the SIOP protocol, Nantes retrospective study of 62 cases over 10 years. <https://www.archive.bu.univ.nantes.fr>.
3. Collins A, Demarche M, Dresse MF, Forget P, Lombet J, Jamblin P, et al. [Renal tumors in children. A single center study of 31 cases]. *Rev Med Liege*. 2009; 64(11): 552-559.
4. Weidner M-A. How to shorten the diagnostic delay of cancer in children and adolescents. Proposed means of raising awareness. 2015; not reported.
5. Tahri A, Benchekroun N, Karkouri M, Dahami Z, Sahraoui S, Acharki A, et al. Adult nephroblastoma. About three cases. *Annales d'Urologie*. 2001; 35(5): 257-261.
6. Haouas N, Sahraoui W, Sridi K. Nephroblastoma of the adult. *Progress in Urology*. 2005; 3.
7. Gombé M C, Godet J, Magueye G S. *Cancers in Francophone Africa*. <https://www.iccp-portal.org/system/files/resources/LivreCancer.pdf>.
8. Axt J, Abdallah F, Axt M, Githanga J, Hansen E, Lessan J, et al. Wilms tumor survival in Kenya. *J Pediatr Surg*. 2013; 48(6): 1254-1262.
9. Doumbia AK, Togo P, Fousseyni T. Management of nephroblastoma in Bamako: about 18 cases. 3.
10. Desvignes C, Gorincour G, Coze C, Aschero A, Bourlière-Najean B, Colavolpe N. Kidney and excretory tract tumors in children. *EM-Consult*. 2013; 13.
11. Bianda NB, Kazadi M, Mputu-Yamba JB. Profile of abdominal masses in children and adolescents in Kinshasa. *Congo méd*. 1993; 484-488.
12. Luntala M. Elements of approach for the ideal treatment of Wilms' tumor at the University Clinics of Kinshasa. Specialization thesis in surgery. 1982.
13. Kongolo K.: Problematic of the treatment of nephroblastoma at the University Clinics of Kinshasa. Dissertation for specialization in Surgery. 1990.
14. Palangi M. Profil épidémiologique et anatomoclinique des tumeurs malignes solides de l'enfant Zaïrois, Mémoire de spécialisation en anatomie pathologique. 1987.
15. Kazadi M. Abdominal masses in children and adolescents at the University Clinics of Kinshasa. 1994.
16. Management of Pediatric Cancers at the University Clinics of Kinshasa. Service d'hémo-Oncologie Pédiatrique/CUK/October. 2019.
17. DIAKITE F. et al. Nephroblastoma: Epidemiological and therapeutic aspects at Donka Hospital in Conakry from 2007 to 2012. *Rev int sc med Abj - RISM*. 2019; 21(1): 50-53.
18. Atanda AT, Anyanwu L-JC, Atanda OJ, Mohammad AM, Abdullahi LB, Farinyaro AU. Wilms' tumour: Determinants of prognosis in an African setting. *Afr J Paediatr Surg*. 2015; 12(3): 171-176.
19. Moulot MO, Ehua M, Agbara K, Kopoin J, Coulibaly D, Yao K. Nephroblastoma in pediatric surgery at chu de treichville (abidjan - cote d'ivoire). *J afr fr chir ped*. 2018; 1(2): 412-417.
20. KANTE A. et al. Nephroblastoma in Mali: about a follow-up of 40 cases, 2017.
21. Bouzahir M. Clinical, paraclinical, epidemiological and therapeutic aspects of nephroblastoma. 2021.
22. Fofana N. Metastatic nephroblastoma at the pediatric oncology unit of CHU Gabriel Touré: clinical, radiological, therapeutic and evolutionary aspects. 2012.
23. Rouzic M-AL. Concordance between clinico-radiological signs of suspected nephroblastoma tumor rupture at diagnosis and post-chemotherapy histological analysis: consequences on the therapeutic choice in a monocentric series from the CHRU of Nancy. 107.
24. Roux C. Molecular classification of Wilms' Tumors by RNA-Seq analysis. 2020.
25. Zrig A. et al. Semiological characteristics of nephroblastomas on imaging. 2014; 601.
26. Kadrin. Management of Nephroblastoma in the HOP department of Marrakech. 2021.



GLOBAL JOURNAL OF MEDICAL RESEARCH: D
RADIOLOGY, DIAGNOSTIC AND INSTRUMENTATION
Volume 23 Issue 1 Version 1.0 Year 2023
Type: Double Blind Peer Reviewed International Research Journal
Publisher: Global Journals
Online ISSN: 2249-4618 & Print ISSN: 0975-5888

Axillary Nodal Metastases - Prediction by Ultrasound and Digital Mammogram Features of Primary Breast Malignancy

By Dr. Sana Shaikh, Dr. Kashaf Anwar Arain & Aiman Rahim

Abstract- Objective: We have evaluated the value of using the ultrasound and mammographic features of primary breast malignancy to predict axillary lymph node metastasis in patients with known biopsy proven breast cancer. We also determined the impact of demographic factors and various histopathological features of breast cancer on axillary lymph nodes metastasis.

Methods: This descriptive retrospective study was an institutional review board-approved study with a waiver of informed consent. Imaging features from 354 patients with digital mammogram and preliminary sonography and histopathological features of invasive breast carcinomas, between March 2021 and August 2022 were compared with axillary lymph node status for the presence of metastases. We did univariate and multivariate logistic regression analysis for this purpose.

Keywords: breast cancer, axillary lymph nodes, metastases, axillary lymph nodes metastases.

GJMR-D Classification: NLM: WP 800



Strictly as per the compliance and regulations of:



© 2023. Dr. Sana Shaikh, Dr. Kashaf Anwar Arain & Aiman Rahim. This research/review article is distributed under the terms of the Attribution-NonCommercial-NoDerivatives 4.0 International (CC BY-NC-ND 4.0). You must give appropriate credit to authors and reference this article if parts of the article are reproduced in any manner. Applicable licensing terms are at <https://creativecommons.org/licenses/by-nc-nd/4.0/>.

Axillary Nodal Metastases - Prediction by Ultrasound and Digital Mammogram Features of Primary Breast Malignancy

Dr. Sana Shaikh^α, Dr. Kashaf Anwar Arain^σ & Aiman Rahim^ρ

Abstract- Objective: We have evaluated the value of using the ultrasound and mammographic features of primary breast malignancy to predict axillary lymph node metastasis in patients with known biopsy proven breast cancer. We also determined the impact of demographic factors and various histopathological features of breast cancer on axillary lymph nodes metastasis.

Methods: This descriptive retrospective study was an institutional review board-approved study with a waiver of informed consent. Imaging features from 354 patients with digital mammogram and preliminary sonography and histopathological features of invasive breast carcinomas, between March 2021 and August 2022 were compared with axillary lymph node status for the presence of metastases. We did univariate and multivariate logistic regression analysis for this purpose.

Results: We studied that predictive factors of axillary lymph nodes metastases were size, shape, margins and posterior features of malignant masses of breast. Skin involvement is also a risk factor for metastatic lymphadenopathy. Some histopathological features i.e. grade of invasive tumor and lymphovascular invasion status also positively correlates with the presence of malignant axillary lymph nodes.

Conclusions: The prognosis of patients with invasive breast carcinomas can be predicted by numerous factors in which identification of metastasis in axillary lymph nodes has important role. There is always a need for minimally invasive examination method with less morbidity and less physical damage. Predictors of axillary lymph node metastasis by imaging characteristics of primary breast masses and its associated features provide insightful results and can become standard of care for assessment of axillary status.

Keywords: breast cancer, axillary lymph nodes, metastases, axillary lymph nodes metastases.

Corresponding Author α: Radiology department. Sindh Institute of Urology and Transplantation. Karachi. Pakistan. e-mail: docsanashaikh@gmail.com

Author σ: Radiology department. Sindh Institute of Urology and Transplantation. Karachi. Pakistan. e-mail: kashaf.anwar81@gmail.com

Author ρ: 2nd year student. Dow medical college. Dow University of Health and Sciences. e-mail: aimanrahim@2001@gmail.com

I. INTRODUCTION

Breast cancer is a diverse family of disease. It gives rise to major threat to social economy and women's health and has called attention from researchers for many years [1, 2]. Pakistan has the highest incidence rate in Asia, with approximately one in every nine women suffering from breast cancer [3]. Early and timely detection of breast cancer can bring down morbidity and mortality related with this disease process [4]. The prognosis of patients with invasive breast carcinomas can be predicted by numerous factors in which identification of metastasis in axillary lymph nodes is pivotal. It is also essential for developing appropriate treatment regimes. Axillary lymph nodes metastasis is also the key predictor of overall survival and recurrence. While the 5-year survival rate for patients with disease localized to the breast is 98.8%, these numbers drops to 85.8% for patients with axillary lymph nodes metastases (AXLN). Staging the axilla for the presence of axillary lymph node (LN) metastasis, the number and location of positive LNs is of prime importance, as it determines the pathologic stage of breast cancer [5-7].

Although the invasive, standard of care, surgical means of staging axilla via sentinel lymph node biopsy (SLNB) or axillary lymph node dissection (ALND) are critical in customizing the treatment with adjuvant chemotherapy or radiotherapy, morbidity and complications associated with these surgical procedures are exigent and require an alternate less invasive system of practice. Hence, imaging of breast and axilla via ultrasound and mammogram has already drawn interest for preoperative staging as a part of minimally invasive approaches in the investigation of the axilla [8]. Magnetic resonance imaging as an adjunct to mammography and ultrasound refines the precision of the estimate of the true magnitude of disease in the affected and contralateral breast. It also improves accuracy of depiction of multicentric disease and sonographically occult disease in axilla [9].

Recent researches have shown important imaging predictors of AXLN metastasis, i.e. tumor size, tumor quadrant, local invasion status, pathologic type, and molecular subtypes. [8-13]. In this retrospective study, we have evaluated the value of using the

ultrasound and mammographic features of primary breast malignancy to predict AXLN in patients with known biopsy proven breast cancer. We also determined the impact of demographic factors and various histopathological features of breast cancer on axillary lymph nodes metastasis.

II. MATERIAL AND METHODS

a) Study population

This study was carried out at the Radiology Department of Sindh Institute of Urology and Transplantation (SIUT) Karachi. The requirement of individual informed consent for this descriptive retrospective study was waived by our institutional ethics committee.

b) Inclusion criteria

Pertinent information was collected from ultrasound and mammogram images.

1. Patients from both the screening and symptomatic populations.
2. Patients with pathologically diagnosed breast cancer.
3. Axillary lymph nodes status illustrated either by FNAC (Fine needle aspiration cytology), trucut biopsy or SNLBX (Sentinel lymph node biopsy).

c) Exclusion criteria

1. Imaging, including baseline breast and axillary ultrasounds, mammograms and histopathological analysis done outside our institution were excluded from this study.
2. Patients with incomplete records and unsatisfactory images.
3. Ductal carcinoma in situ (DCIS) were also excluded from the study.
4. Patients who have undergone neo-adjuvant chemotherapy.
5. Patients without histopathological diagnosis of axillary lymph nodes.
6. Bilateral breast cancers were also excluded from the study because of very few cases of bilateral breast cancers.

In this way, data from 354 patients with breast cancer were retrospectively collected between March 2021 and August 2022.

d) Ultrasound

All breast and axillary ultrasound examinations were not done under research study settings and were carried out according to the standard of care protocol, in accordance with ACR practice parameters for the performance of a breast ultrasound examination (revised 2016) [14] as a routine practice of our breast cancer unit. For sonography, Canon Xario 200 was used, with frequency of 14 MHz. Every ultrasound examination included both breasts and both axillary regions.

e) Digital Mammography

All mammograms were done with Selenia Dimensions 3D Digital Mammography Tomosynthesis System (Hologic, Bedford, MA, USA). Images were reviewed on high-resolution workstations. These were performed according to ACR practice parameters for the performance of screening and diagnostic mammography (revised 2018) [15]. Two standard views (craniocaudal CC and mediolateral oblique MLO) were performed as per usual for all patients. Accessory views were taken where required.

f) Ultrasound and Digital Mammogram Assessment

All ultrasound and mammogram images were reviewed by 1 of 3 senior consultant radiologist in breast imaging with at least 5 years of experience each, in breast imaging. In the case of discrepancies, a consensus was reached after discussion. The sonographic and mammographic characteristics of the breast carcinomas and axillary lymph nodes were evaluated based on the standard criteria of Breast Imaging Reporting and Data System (BIRADS). For mammogram, the features that were assessed were enumerated in Table 2 and Table 3. For ultrasound, the features of primary breast malignancy and axillary lymph nodes were itemized in Table 2 and Table 4.

Data on patient's demographics and tumor characteristics, diagnostic work-up, and histopathological outcome of the axillary lymph nodes were retrospectively collected. Tissue sampling of axilla was performed in case of suspicious axillary lymph node(s). It was done either by core needle technique by using 18 gauge core needle, or by FNAC (when core needle biopsy was technically difficult).

Mammography has lower sensitivity for imaging of axilla because most of the axilla is pushed out of the image field after compression, even in dedicated axillary tail views of mammogram. Ultrasound is reported to be convincing examination used routinely in evaluation of lymph node involvement [4], therefore most suspicious looking lymph node on the basis of ultrasound features was selected for tissue sampling.

g) Biomarker status of the breast mass

Histopathological evaluation was done to assess morphological type of breast cancer and immunohistochemical analysis was also done on breast mass to assess ER, PR, Ki-67 index, and Her-2 neu expression. ER and PR were regarded as positive if at least 1% of the tumor nuclei were positively stained [10]. An additional fluorescence in situ hybridization (FISH) was analyzed to detect Her-2 positivity with scores of 2 or higher. Scores of 1 or 0 were defined as Her-2 negative [10]. Ki-67 index >14% was considered as high and <14% was considered as low expression.

h) *Statistical analysis*

All the data was entered and analyzed in SPSS version 22.0. Mean and standard deviations were computed for continuous variables and categorical variables were presented as frequency and percentages and their comparison was done using bivariate Chi-square test. Multivariate binary logistic analysis was used to quantify the relative contribution of each imaging feature. P-value <0.05 was considered as significant. Odds ratios and confidence intervals were recorded for predictors of AXLN metastases.

III. RESULTS

a) *Demographics and AXLN metastases: (Table1)*

In our data set, the median age of patients were 48.0 (+/- 11.3 S.D), out of which the majority of cancers were detected in 20-45 years of age. Among 354

patients (n=220, 62.1%) have axillary lymph node metastases (AXLN) metastases. (n=134, 37.9%) have biopsy proven benign lymph nodes. On ultrasound axilla (n= 144) show benign morphology. Among these benign looking lymph nodes (n= 66, 45.8%) turned out be malignant. (n= 78, 54.2%) share same benign morphology on histopathology as well. (n=148) are of intermediate suspicion. Among these (n= 118, 79.7%) were malignant and (n = 30, 20.3%) were benign. Among (n=62) malignant looking lymph nodes (n=36, 58.1%) were truly malignant on biopsy.

Most common complaint was lump (n=322), followed by pain (n= 20), both lump and pain (n= 6) and nipple discharge (6). Patient's age, complaints, side of tumor, family history and menopausal status did not show correlation with AXLN status.

Table 1: Demographic characteristics and axillary lymph nodes metastases

Demographics	Total (n = 354)	Metastatic *AXLN (n = 220) (%)	Non-metastatic *AXLN (n =134) (%)	p-value
Age				0.7
20 – 45	162	102 (63.0%)	60 (37.0%)	
46 - 50	52	34 (65.4%)	18 (34.6%)	
50 above	140	84 (60.0%)	56 (40.0%)	
Complaints				0.09
lump	322	204 (63.4%)	118 (36.6%)	
lump and pain	6	4 (66.7%)	2 (33.3%)	
nipple discharge	6	4 (66.7%)	2 (33.3%)	
Only pain	20	8 (40.0%)	12 (60.0%)	
Side				0.2
Right	182	118 (64.8%)	64 (35.2%)	
Left	172	102 (59.3%)	70 (40.7%)	
Family History				0.1
Yes	122	70(57.4%)	52 (42.6%)	
No	232	150(64.7%)	82 (35.3%)	
Lactation history				0.04
Yes	282	168 (59.6%)	114 (40.4%)	
No	72	52 (72.2%)	20 (27.8%)	
Menopause				0.2
Yes	182	118 (64.8%)	64 (35.2%)	
No	172	102 (59.3%)	70 (40.7%)	
AXLN on ultrasound				<0.01
Benign	144	66 (45.8%)	78 (54.2%)	
Intermediate suspicious	148	118 (79.7%)	30 (20.3%)	
Malignant	62	36 (58.1%)	26 (41.9%)	

*AXLN = Axillary lymph nodes

b) *Imaging findings on ultrasound and mammogram and AXLN metastases: (Table 2, 3 and 4)*

Size, shape and margins of the tumor on ultrasound and digital mammogram exhibited notable association with presence of metastases in AXLN. Irregular shape (n=318) and irregular / spiculated margins (n= 315) are significantly related to presence of metastatic axillary lymph nodes (n=204, 64.2 %) and (n=202, 64.1%) respectively. All tumors with circumscribed margins (n= 6) have benign lymph nodes (n= 6, 100%). We studied that AXLN metastases are more commonly found in large size of invasive breast cancer. In tumors larger than 5cm (n=144), 116(80.6%) have malignant lymph nodes, and tumors less than 2 cm (22) have only (n=8, 36.4%) positive AXLN. Posterior features of breast malignancy also expressed positive trend. Posterior acoustic shadowing (n=86) have highest percentage of metastatic AXLN (n= 64, 74.4%). Rest of the ultrasound feature of breast mass i.e. echogenicity, orientation and boundary are not correlated with AXLN metastases.

Global asymmetry in the breast also unveiled positive association. (n= 70) patients have globally

enlarged edematous breast and (n= 50, 71.4%) have AXLN metastases. In globally small shrinking breasts (n= 10), (n= 4, 40.0% have metastases and (n=6, 60.0%) have benign lymph nodes. In our study, finding of diffuse skin thickening along with blurring of subcutaneous fat planes (n= 58) has noteworthy link. All of these patients have AXLN metastases.

BIRADS V show more significant association with positive AXLNs than BIRADS IV. In BIRADS V (n= 60), (n = 44, (73.3%) have positive AXLN and only (n=16, 26.7%) have LNs with benign findings. No association is found with multifocality / multicentricity of the breast tumors.

In our study positive correlation of breast density has also been demonstrated. Dense breasts (Type B, n= 124) and (Type C, n= 184) are associated more with the presence of AXLN metastases (n= 80, 64.5%) and (n= 126, 68.5%) respectively. Type A (n= 46) showed high percentage of (n=32, 69.6%) non-metastatic LNs.

Table 2: Imaging (Combined Mammogram and Sonographic features of breast masses) and axillary lymph nodes metastases

Imaging findings	Total (n=354)	Metastatic *AXLN (n=220) (%)	Non-metastatic *AXLN (n= 134) (%)	p-value
Size				
<2cm	22	8 (36.4 %)	14 (63.6%)	0.00
2-5cm	188	96 (51.1%)	92 (48.9%)	
>5cm	144	116 (80.6%)	28 (19.4%)	
Shape				
Oval	28	12 (42.9%)	16 (57.1%)	0.06
Round	8	4 (50.0%)	4 (50.0%)	
Irregular	318	204 (64.2%)	114 (35.8%)	
Margins				
Circumscribed	6	0 (0.0%)	6 (100.0%)	0.04
Microlobulated	33	18 (54.5%)	15 (45.5%)	
Irregular/spiculated	315	202 (64.1%)	113 (35.9%)	
Architectural distortion / Trabecular thickening				
Yes	312	192(61.5%)	120 (38.5%)	0.4
No	42	28 (66.7%)	14 (33.3%)	
Multifocality / Multicentricity				
Yes	58	36 (62.1%)	22 (37.9%)	0.9
No	296	184 (62.2%)	112(37.8%)	
Asymmetry				
No	258	160 (62.0%)	98 (38.0%)	0.03
Global- small	10	4 (40.0%)	6 (60.0%)	
Global- Enlarged	70	50 (71.4%)	20 (28.6%)	
Focal	16	6 (37.5%)	10 (62.5%)	
Skin				
Not involved	245	134 (54.7%)	111 (45.3%)	<0.01
Focal dimpling	30	16 (53.3%)	14 (46.7%)	
Diffuse thickening	21	12(57.1%)	9 (42.9%)	
Diffuse thickening + blurring of subcutaneous fat	58	58 (100.0%)	0 (0.0%)	

BIRADS			
III	8	2 (25.0%)	6 (75.0%)
IV	252	146 (57.9%)	106 (42.1%)
V	60	44 (73.3%)	16 (26.7%)
VI	34	28 (82.4%)	6 (17.6%)

*AXLN = Axillary lymph nodes

Table 3: Imaging findings specific to mammogram and axillary lymph nodes metastases

Imaging findings	Total (n=354)	Metastatic *AXLN (n=220) (%)	Non-metastatic *AXLN (n= 134) (%)	p-value
Breast density				0.00
A	46	14 (30.4%)	32 (69.6%)	
B	124	80 (64.5%)	44 (35.5%)	
C	184	126 (68.5%)	58(31.5%)	
D	0	0	0	
Microcalcifications				0.01
None	282	166 (58.9%)	116 (41.1%)	
Within the mass	60	42 (70.0%)	18 (30.0%)	
Outside the mass	2	2 (100.0%)	0 (0.0%)	
Both within and outside the mass	10	10 (100.0%)	0 0.0%	

*AXLN = Axillary lymph nodes

Table 4: Imaging findings specific to ultrasound and axillary lymph nodes metastases:

Ultrasound Only	Total	Metastatic *AXLN	Non-metastatic *AXLN	p-value
Echo pattern				0.06
Anechoic	2	0 (0.0%)	2 (100.0%)	
Hypoechoic	306	186 (60.8%)	120 (39.2%)	
Hyper echoic	4	4 (100.0%)	0 (0.0%)	
Iso echoic	4	4 (100.0%)	0 (0.0%)	
Complex	38	26 (68.4%)	12 (31.6%)	
Posterior features				0.01
Enhancement	46	30 (65.2%)	16 (34.8%)	
Shadowing	86	64 (74.4%)	22 (25.6%)	
Both	216	126 (58.3%)	90 (41.7%)	
None	6	0 (0.0%)	6 (100.0%)	
Orientation				0.5
Parallel	60	40 (66.7%)	20 (33.3%)	
Anti-parallel	280	170 (60.7%)	110 (39.3%)	
Cannot be assessed	14	10 (71.4%)	4 (28.6%)	
Boundary				0.7
Abrupt	188	116 (61.7%)	72 (38.3%)	
Echogenic halo	164	104 (63.4%)	60 (36.6%)	

*AXLN = Axillary lymph nodes

c) *Histopathological characteristics of breast malignancy and AXLN metastases: (Table 5)*

In our study grade of invasive breast cancer and lymphovascular invasion (LVI) showed positive correlation with the presence of AXLN metastases. All grade II and III tumors (n= 28) and (n= 172) respectively, are associated with malignant LNs. On the contrary, grade I tumors (n=154) showed (n= 134, 87%) non-malignant lymph nodes. LVI is also directly proportional to the presence of metastases. Tumors that showed LVI are (n=242). Among these (n=170, 70.2%)

have AXLN metastases. On the other hand, luminal subtypes, Ki-67 and Her-2neu show no positive linkage.

Table 5: Histopathological characteristics of breast masses and axillary lymph nodes metastases

HP	Total	Metastatic *AXLN	Non-metastatic *AXLN	p-value
Luminal Classification				
A	76	54 (71.1%)	22 (28.9%)	0.1
B	158	94 (59.5%)	64 (40.5%)	
Her-2 enrich	64	42 (65.6%)	22 (34.4%)	
TNBC	56	30 (53.6%)	26 (46.4%)	
*TNBC v/s *Non-TNBC				
TNBC	64	42 (65.6%)	22 (34.4%)	0.5
Non-TNBC	290	178 (61.4%)	112 (38.6%)	
Grade				
I	154	20 (13.0%)	134 (87.0%)	<0.01
II	28	28 (100.0%)	0 (0.0%)	
III	172	172 (100.0%)	0 (0.0%)	
Ki-67				
<14	70	44 (62.9%)	26 (37.1%)	0.6
>14	80	46 (57.5%)	34 (42.5%)	
>30	204	130 (63.7%)	74 (36.3%)	
Her-2neu				
+ve	198	124 (62.6%)	74 (37.4%)	0.8
-ve	156	96 (61.5%)	60 (38.5%)	
LVI				
Presence	242	170 (70.2%)	72 (29.8%)	<0.01
Absence	112	50 (44.6%)	62 (55.4%)	

*AXLN = Axillary lymph nodes.

*TNBC = Triple negative breast cancer.

*Non-TNBNC = Non- triple negative breast cancer.

d) *Multivariate analysis: (Table 6)*

We also performed multivariate analysis by combining imaging findings. Irregular spiculated margins of invasive breast carcinomas are strongly associated with absence of benign LNs. (p=0.03) (OR= 2.086)(CI= 1.067 - 4.077). Combining features of tumors, like size of 2-5 / 5cm, posterior acoustic

shadowing and irregular spiculated margins increased significantly the probability of AXLN being metastatic. (p=0.01)(OR= 2.041)(CI= 1.163 - 3.579). Combining imaging features of diffuse skin thickening with diffuse skin thickening and blurring of subcutaneous fat showed significant relationship with AXLN positivity. (p=<0.01)(OR= 6.481)(CI= 3.113 - 13.497).

Table 6: Multivariate analysis of ultrasound and mammographic findings:

Imaging Findings	Outcome variable	p-value	Odds ratio	Confidence Interval
Irregular spiculated margins of v/s others	AXLN metastases v/s AXLN no metastases	.032	2.086	1.067 - 4.077
2-5 / >5 cm mass + posterior acoustic shadowing	AXLN metastases v/s AXLN no metastases	0.01	2.04	1.163 - 3.579
2-5 / >5cm mass + irregular spiculated margins	AXLN metastases v/s AXLN no metastases	.002	2.438	1.382 - 4.300
2-5 / 5cm + posterior acoustic shadowing + irregular spiculated margins	AXLN metastases v/s AXLN no metastases	.013	2.041	1.163 - 3.579
Diffuse skin thickening +Diffuse skin thickening and blurring of subcutaneous fat	AXLN metastases v/s AXLN no metastases	.000	6.481	3.113 - 13.497

*AXLN = Axillary lymph nodes

IV. DISCUSSION

We studied prediction of AXLN metastasis in patients with known biopsy proven breast cancer, using ultrasound and mammographic features of primary breast malignancy. We also determined the impact of demographic factors and various histopathological features of breast cancer on AXLN metastasis. We studied that size and margins of the mass on imaging, posterior features of the mass on ultrasound and involvement of skin of breast strongly correlates with AXLN metastases. Breast density on mammogram also showed positive trend. Histopathological factors that showed strong correlation with presence of AXLN metastases are tumor grade and LVI.

T stage of invasive breast cancer is represented by tumor size. It is most simple yet principal predictor for AXLN metastasis. Our study also established this finding that large tumor size ($p = <0.01$) has higher incidence of metastatic involvement of axilla [6]. This finding is in accordance with previous study showing that increase in tumor size has direct relationship with AXLN metastasis [13] [16] [17]. This implies the importance of early and timely detection of breast cancer [4].

Another important predictor of AXLN metastases are shape and margins of tumor. Our study showed borderline significance with shape of the tumor mass. Association of irregular shape and margins of tumor with AXLN metastases have been established in previous studies as well [5]. The shape of a tumor has some specific growth patterns, which makes it an important predictor of metastatic spread. Irregular shape of malignant tumors represent an infiltrative growth style, which is also fast growing in nature. This rapid growth pattern predisposes cancer cells to penetrate surrounding tissues, including blood vessels and lymphatic leading to axillary lymph node metastasis. Conversely, round shape of the tumor is believed to be slow growing and have benign propensity [5].

In our study, along with the size, irregular shape and irregular margins of invasive breast cancer, another important tumor characteristic serving as a predictor of LN involvement in axilla is posterior acoustic feature on ultrasound. Posterior acoustic shadow thought to arise from stromal fibrosis and desmoplastic reaction and it is a well-known feature of malignant breast masses. We postulate that relatively longer growth pattern of these tumors with posterior acoustic shadowing represent a higher risk of AXLN involvement [6] [13] [18]. Multivariate logistic regression analysis done in our study, showed strong interrelationship of tumor size 2-5 / 5cm, along with posterior acoustic shadowing and irregular margins/shape of the tumor with malignant AXLN. [Figure 1 (a) (b)]. In our study no correlation is found with mass boundary and orientation on sonography, however Luo et.al [1] proposed that lesion boundary and Wang et.al. [17] documented that vertical

orientation was independently associated with malignant AXLN.

We found out that skin changes are independent predictors of malignant status of AXLN. Multivariate analysis of diffuse thickening of skin alone, along with diffuse thickening and blurring of subcutaneous fat displayed convincing positive association. Invasive breast carcinomas are known to demonstrate secondary signs of skin changes in involved breast. It can present either as direct focal retraction and adhesion of tumor with the overlying skin, or in more generalized thickening, commonly associated with presence of edema in the breast parenchyma. Edema and subcutaneous fat layer blurring are caused by the distension of blood vessels and lymphatics in the breast [19]. Some studies also showed correlation of AXLN metastases with distance of tumor from the skin [20]. Lymphovascular invasion (LVI) is another dominant histopathological predictor of AXLN metastasis. Our study also showed LVI to be an independent risk factor. Presence of lymphovascular tumor emboli is a well-founded indicator for distant metastasis and overall survival in breast cancer [19]. LVI and presence of AXLN metastases can also be correlated with the presence of diffuse thickening and blurring of subcutaneous fat on mammograms. [Figure 2 (a) (b)]. We also studied positive trend of high grade tumors with malignant AXLN. High histopathological grade represents invasiveness and are proven to be associated with more advance and aggressive disease, and showed link with extensive malignant nodal disease in axilla [1] [16] [17] [21].

We did not recognize association of morphological type of breast cancer, immunohistochemical (IHC) subtypes, Ki-67 and Her-2 status with axillary nodal status. Similarly, Shaikh S [18] had studied sono-mammometry score in prognostication of IHC subtypes of breast carcinomas, also documented no association with of IHC subtypes with nodal stage. Contrarily, Li et.al.[6] studied that pathological type of invasive breast cancer, IHC subtype and Her-2 positivity are associated with heavy nodal tumor burden. Similarly, Luo et.al [1] proposed similar kind of association of IHC markers and Ki-67 with AXLN status.

Breast density and BIRADS also demonstrated positive link with AXLN status. Dense breasts on mammogram are shown to have substantial association with malignant LNs. One explanation of this finding can be related to the younger mean age of our patient's cohort i.e. 48.0 (+/- 11.3 S.D). We also speculate that dense fibroglandular parenchyma of the breast on mammogram can lead to delay in the diagnosis of invasive breast carcinomas and therefore show positive trend towards AXLN metastases. The ACR- BIRADS score is also a well approved reporting method to anticipate invasiveness of tumors. In our study BIRADS

V show more significant association with positive AXLNs than BIRADS IV, which points towards increasing aggressive behaviour with increase in BIRADS score [6].

In our study morphology of axillary lymph nodes on axillary ultrasound is strongly associated with metastatic nodal status. Lartigue et.al [22] had showed ultrasonography to be an effective modality for the detection of LN metastases. There are some suggested imaging parameters for malignant lymph nodes, which is a separate wide research area and out of the scope of this study. [Figure 3(a)(b)].

Our study has some limitations. First, our study included small numbers of patients with retrospective evaluation of data. Real time verification on ultrasound was missing. Prospective studies and increasing the sample size are needed to authenticate these results.

Strength of our study, however, includes histopathological correlation of all axillary LNs, either by percutaneous biopsy, FNAC or SNLBX.

V. CONCLUSION

Breast cancer is a heterogeneous group of disease. Early and timely detection of breast cancer has

significant impact on prognosis related with this disease process. The prognosis of patients with invasive breast carcinomas can also be predicted by numerous factors in which identification of metastasis in axillary lymph nodes has important role. Sentinel lymph node biopsy, although reliable and established method in invasive breast cancer for the assessment of axillary status, there is always a need for minimally invasive examination method with less morbidity and less physical damage. Predictors of axillary lymph node metastasis by imaging characteristics of primary breast masses and its associated features provide insightful results and can become standard of care for assessment of axillary status.

Abbreviations:

AXLN: Axillary lymph nodes metastases.

LNs: Lymph nodes.

IHC: Immunohistochemical.

TNBC: Triple negative breast cancer.

Non-TNBC: Non- triple negative breast cancer.

LVI: Lymphovascular invasion.

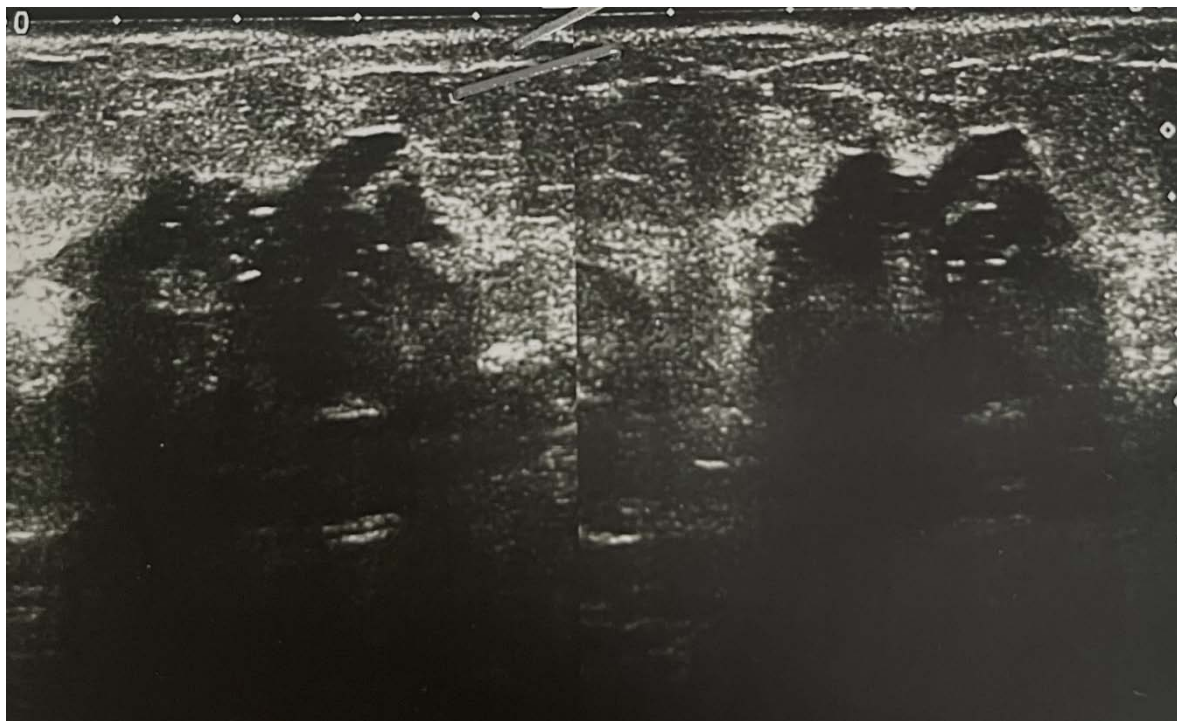


Figure 1(a): Biopsy proven invasive breast carcinoma. Ultrasound shows hypoechoic mass with irregular spiculated margins and dense posterior acoustic shadowing.

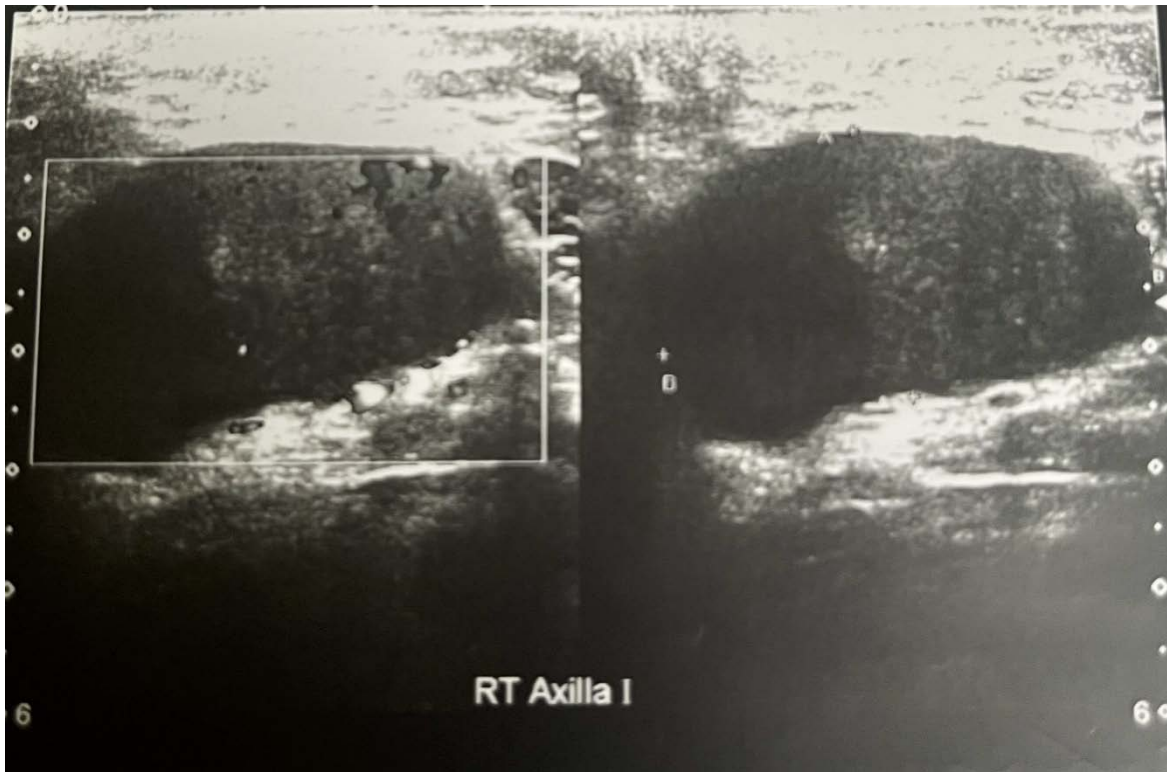
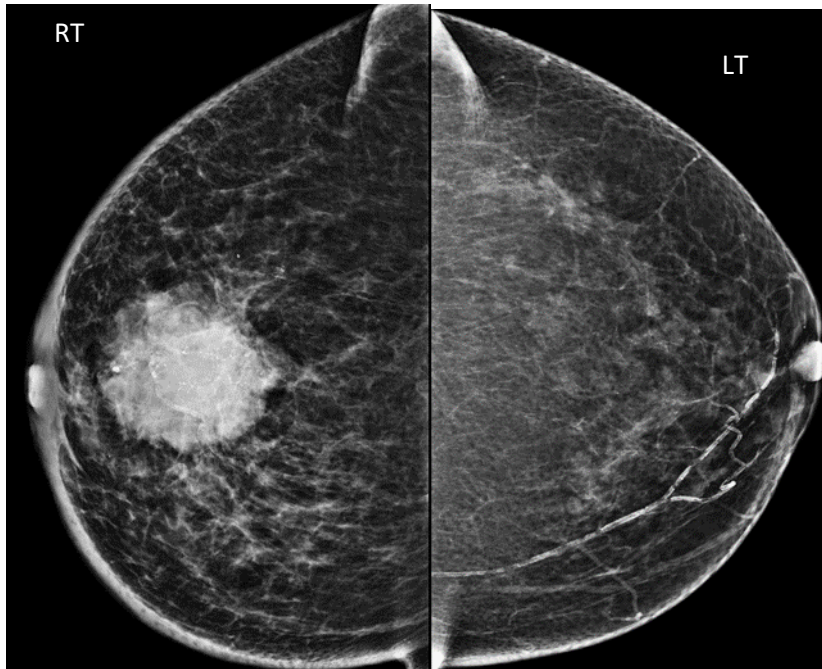


Figure 1(b): Ultrasound axilla of same patient as in Figure 1(a). It shows large malignant looking axillary lymph node.



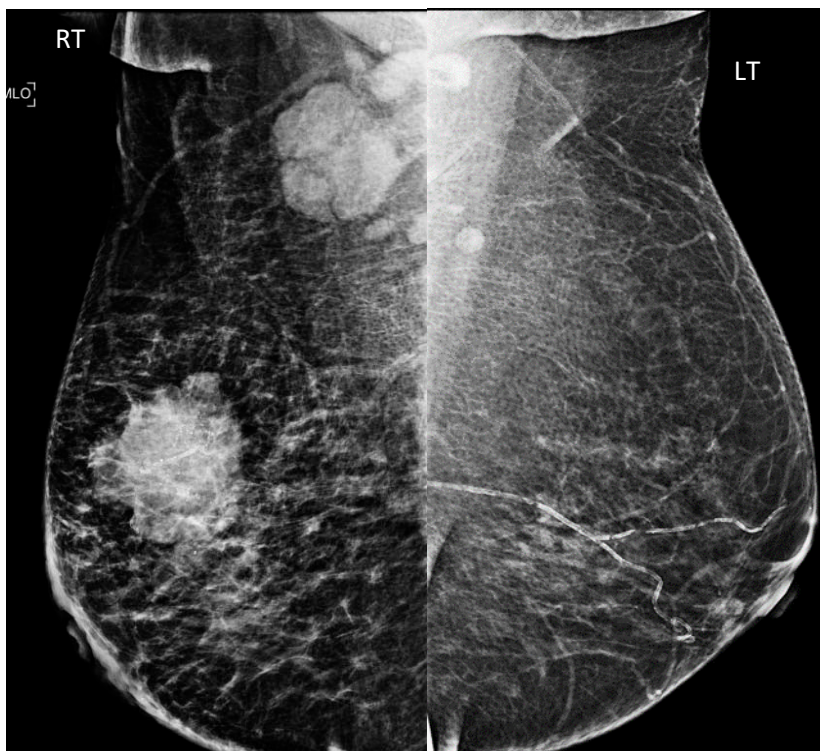


Figure 2 (a): Digital mammogram shows a high density mass with irregular margins. Mild diffuse skin thickening with blurring of fat planes are also seen. There is a large malignant looking nodal mass in ipsilateral axilla.

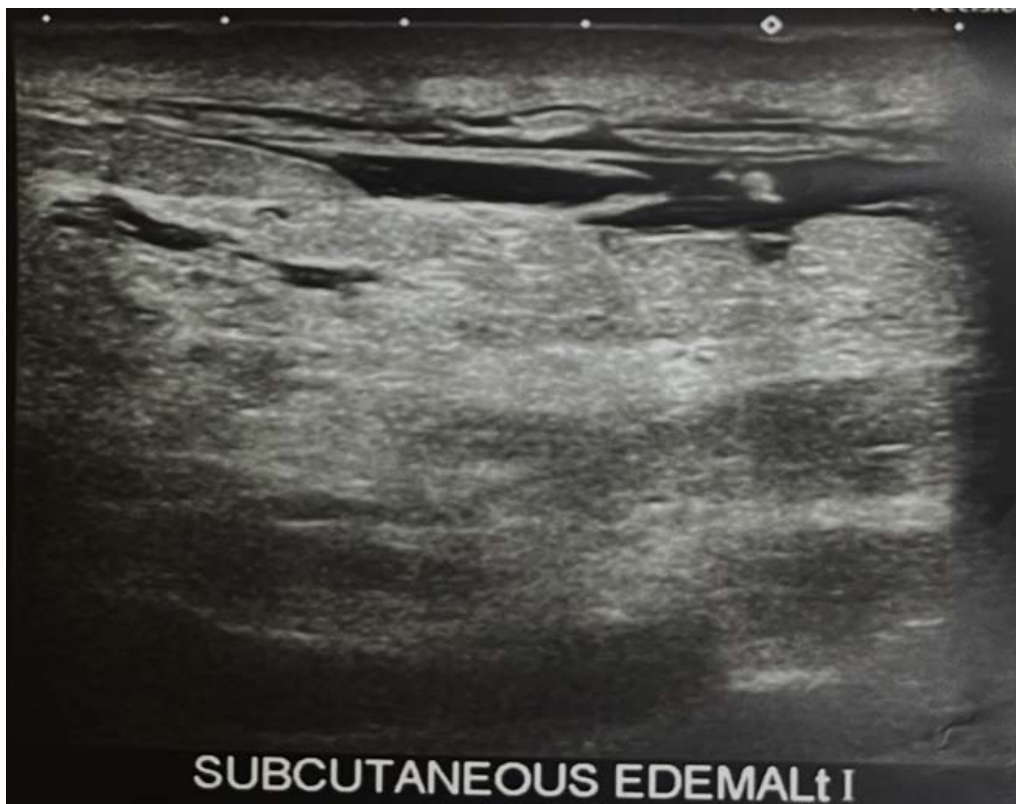


Figure 2(b): Ultrasound of the same patient as in figure 2(a). Diffuse skin thickening along with interstitial edema is noticed on this image. (Malignant mass is not shown here).

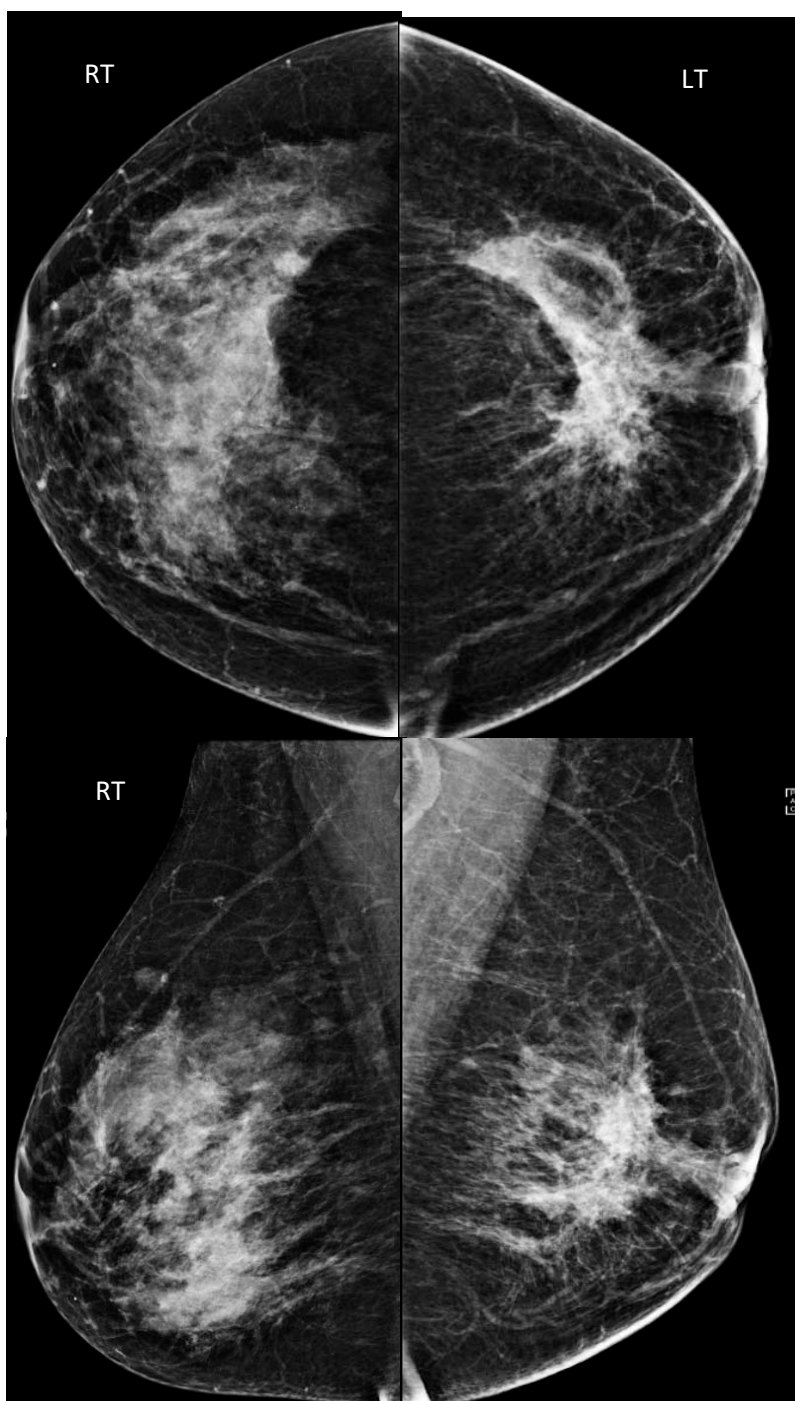


Figure 3(a): Mammogram shows a high density mass with irregular shape and irregular spiculated margins in retroareolar region of left breast. Mild focal retraction of overlying skin is seen. Partial visualization of an axillary lymph node is seen. Right breast displays increase breast density.



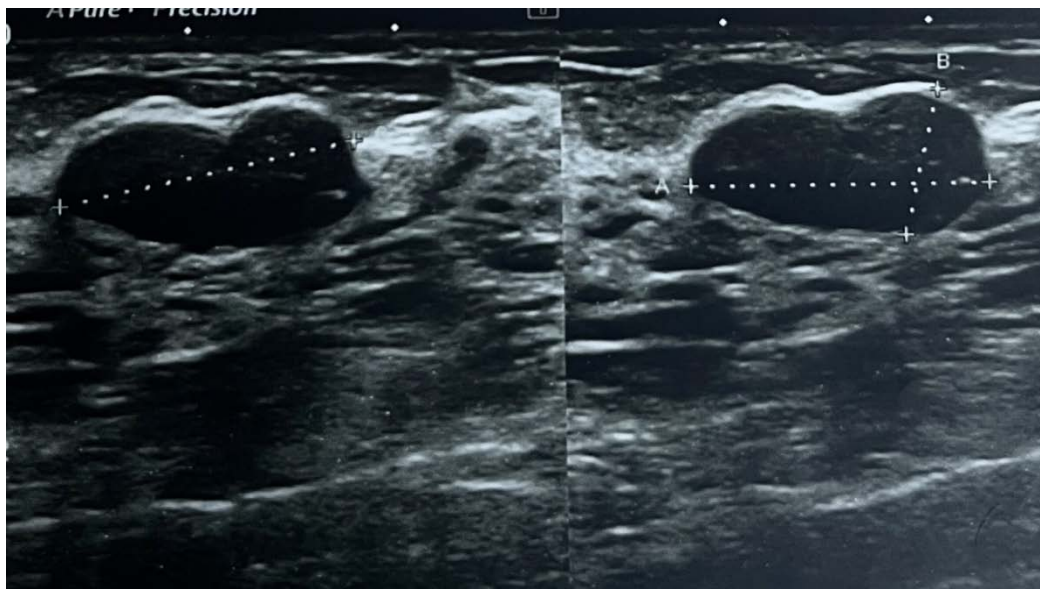
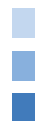

Figure 3(b): Ultrasound left axilla of same patient as in figure 3(a). There is malignant looking lymph node which was not imaged on mammogram.

REFERENCES RÉFÉRENCES REFERENCIAS

- Luo Y, Zhao C, Gao Y, Xiao M, Li W, Zhang J, Ma L, Qin J, Jiang Y, Zhu Q. Predicting Axillary Lymph Node Status With a Nomogram Based on Breast Lesion Ultrasound Features: Performance in N1 Breast Cancer Patients. *Front Oncol.* 2020 Oct 27; 10:581321. Doi: 10.3389/fonc.2020.581321. PMID: 33194714; PMCID: PMC7653095.
- Yang J, Wang T, Yang L, Et Al. Preoperative prediction of axillary lymph node metastases in breast cancer using mammography-based radiomics method. *Scientific reports.* 2019; 4429.
- Bhurgri Y. Karachi Cancer Registry Data-implications for the National Cancer Control Program of Pakistan. *Asian Pac J Cancer Prev.* 2004, 5: 77-82.
- Khan A, Masroor I, Khandwala K, et al. Utility of Ultrasound and Mammography in Detection of Negative Axillary Nodal Metastasis in Breast Cancer. *January 17 2020;* 10.7759/cureus.6691.
- Guo Q, Dong Z, Zhang L, Ning C. Ultrasound Features of Breast Cancer for Predicting Axillary Lymph Node Metastasis. *J Ultrasound Med* 2018; 37: 1345–1353 | 0278-4297 |
- Li JW, Tong YY, Jiang YZ. Clinicopathologic and Ultrasound Variables Associated With a Heavy Axillary Nodal Tumor Burden in Invasive Breast Carcinoma. *J Ultrasound Med* 2019; 38: 1747–1755 | 0278-4297.
- Chang JM, Leung JWT, Moy L, Ha SM, Moon WK. Axillary Nodal Evaluation in Breast Cancer: State of the Art. *Radiology.* 2020 Jun; 295(3): 500-515. Doi: 10.1148/radiol.2020192534. Epub 2020 Apr 21. PMID: 32315268.
- Kim WH, Kim HJ, Lee SM, Cho SH, Shin KM, Lee SY, Lim JK, Lee WK. Preoperative axillary nodal staging with ultrasound and magnetic resonance imaging: predictive values of quantitative and semantic features. *Br J Radiol.* 2018 Dec; 91(1092): 20180507. doi: 10.1259/bjr.20180507. Epub 2018 Aug 29. PMID: 30059242; PMCID: PMC6319840.
- Assing MA, Patel BK, Karamsadkar N, Weinfurter J, Usmani O, Kiluk JV, Drukteinis JS. A comparison of the diagnostic accuracy of magnetic resonance imaging to axillary ultrasound in the detection of axillary nodal metastases in newly diagnosed breast cancer. *Breast J.* 2017 Nov; 23 (6): 647-655. doi: 10.1111/tbj.12812. Epub 2017 Apr 10. PMID: 28397344.
- Akissue de Camargo Teixeira P, Chala LF, Shimizu C, Filassi JR, Maesaka JY, de Barros N. Axillary Lymph Node Sonographic Features and Breast Tumor Characteristics as Predictors of Malignancy: A Nomogram to Predict Risk. *Ultrasound Med Biol.* 2017 Sep; 43(9): 1837-1845. doi: 10.1016/j.ultrasmedbio.2017.05.003. Epub 2017 Jun 17. PMID: 28629690.
- Zhang J, Li X, Huang R, Feng WL, Kong YN, Xu F, Zhao L, Song QK, Li J, Zhang BN, Fan JH, Qiao YL, Xie XM, Zheng S, He JJ, Wang K. A nomogram to predict the probability of axillary lymph node metastasis in female patients with breast cancer in China: A nationwide, multicenter, 10-year epidemiological study. *Oncotarget.* 2017 May 23; 8(21): 35311-35325. doi: 10.18632/oncotarget.13330. PMID: 27852049; PMCID: PMC5471057.
- Qiu SQ, Zeng HC, Zhang F, et al. A nomogram to predict the probability of axillary lymph node

- metastasis in early breast cancer patients with positive axillary ultrasound. *Sci Rep* 2016; 6:21196.
13. Tong YY, Sun PX, Zhou J, Shi ZT, Chang C, Li JW. The Association Between Ultrasound Features and Biological Properties of Invasive Breast Carcinoma Is Modified by Age, Tumor Size, and the Preoperative Axilla Status. *J Ultrasound Med.* 2020 Jun; 39(6): 1125-1134. doi: 10.1002/jum.15196. Epub 2019 Dec 24. PMID: 31875336.
 14. American College of Radiology, ACR Practice Parameter for the Performance of a Breast Ultrasound Examination, <https://www.acr.org/-/media/ACR/Files/Practice-Parameters/USBreast, 2016>.
 15. American College of Radiology, ACR Practice Parameter for the Performance of Screening and Diagnostic Mammography, <https://www.acr.org//media/ACR/Files/Practice-Parameters/screen-diag-mammo, 2018>.
 16. Upadhyaya VS, Lim GH, Chan EYK, Fook-Chong SMC, Leong LCH. Evaluating the preoperative breast cancer characteristics affecting the accuracy of axillary ultrasound staging. *Breast J.* 2020 Feb; 26(2): 162-167. doi: 10.1111/tbj.13635. Epub 2019 Sep 27. PMID: 31562691.
 17. Wang H, Zhan W, Chen W, Li Y, Chen X, Shen K. Sonography with vertical orientation feature predicts worse disease outcome in triple negative breast cancer. *Breast.* 2020 Feb; 49: 33-40. doi: 10.1016/j.breast.2019.10.006. Epub 2019 Oct 23. PMID: 31677531; PMCID: PMC7375680.
 18. Shaikh S, Rasheed A. Predicting Molecular Subtypes of Breast Cancer with Mammography and Ultrasound Findings: Introduction of Sono-Mammometry Score. *Radiol Res Pract.* 2021 Feb 9; 2021: 6691958. doi: 10.1155/2021/6691958. PMID: 33628504; PMCID: PMC7886512.
 19. Liu, Z., Li, R., Liang, K. et al. Value of digital mammography in predicting lymphovascular invasion of breast cancer. *BMC Cancer* 20, 274 (2020). <https://doi.org/10.1186/s12885-020-6712-z>
 20. Eom YH, Kim EJ, Chae BJ, Song BJ, Jung SS. The distance between breast cancer and the skin is associated with axillary nodal metastasis. *J Surg Oncol.* 2015 Jun; 111(7): 824-8. doi: 10.1002/jso.23898. Epub 2015 Apr 6. PMID: 25847102.
 21. Wu JL, Tseng HS, Yang LH, Wu HK, Kuo SJ, Chen ST, Chen DR. Prediction of axillary lymph node metastases in breast cancer patients based on pathologic information of the primary tumor. *Med Sci Monit.* 2014 Apr 8; 20: 577-81. doi: 10.12659/MSM.890345. PMID: 24714517; PMCID: PMC3989944.
 22. Cools-Lartigue J, Meterissian S. Accuracy of axillary ultrasound in the diagnosis of nodal metastasis in invasive breast cancer: a review. *World J Surg.* 2012 Jan; 36(1): 46-54. doi: 10.1007/s00268-011-1319-9. PMID: 22037691.





This page is intentionally left blank



GLOBAL JOURNAL OF MEDICAL RESEARCH: D
RADIOLOGY, DIAGNOSTIC AND INSTRUMENTATION
Volume 23 Issue 1 Version 1.0 Year 2023
Type: Double Blind Peer Reviewed International Research Journal
Publisher: Global Journals
Online ISSN: 2249-4618 & Print ISSN: 0975-5888

MLC Transmission and Dosimetric Leaf Gap Measurement Using CU Values from Integrated Images of Varian VitalBeam LINAC

By Md. Motiur Rahman, MSc, Md Fajle Rabby, MSc, Mahmuda Akter, MSc, Rubel Ahmed, MSc, MMH Bhuiyan, PhD & MKA Khan, PhD

Jagannath University

Abstract- Modern dynamic radiotherapy techniques require more precision and need routine checking. However, presently available methods for Dosimetric Leaf Gap (DLG) and MLC transmission factor are highly time-consuming, so they are not feasible for busy radiotherapy centers. This analytical and observational study tried to determine the most straightforward way of simultaneously determining the transmission and DLG in the shortest time.

We measured all data at 5cm depth using a Varian VitalBeam LINAC, newly installed at TMSS Cancer Center, Bogura, Bangladesh. We used three significant pieces of equipment in our experiment: an integrated Electronics Portal Imaging Device (EPID), a solid water phantom and a farmer-type ion chamber (Model: IBA FC65-P). The Eclipse™ TPS was also used to make the QA plan and to analyze the images.

Keywords: *electronic portal imaging device (EPID), VMAT, dosimetric leaf gap (DLG), MLC transmission factor, calibration unit (CU).*

GJMR-D Classification: *NLM code: WN 230*



MLCTRANSMISSIONANDDOSIMETRICLEAFGAPMEASUREMENTUSINGCUVALUESFROMINTEGRATEDIMAGESOFVARIANVITALBEAMLINAC

Strictly as per the compliance and regulations of:



© 2023. Md. Motiur Rahman, MSc, Md Fajle Rabby, MSc, Mahmuda Akter, MSc, Rubel Ahmed, MSc, MMH Bhuiyan, PhD & MKA Khan, PhD. This research/review article is distributed under the terms of the Attribution-NonCommercial-NoDerivatives 4.0 International (CC BY-NC-ND 4.0). You must give appropriate credit to authors and reference this article if parts of the article are reproduced in any manner. Applicable licensing terms are at <https://creativecommons.org/licenses/by-nc-nd/4.0/>.

MLC Transmission and Dosimetric Leaf Gap Measurement Using CU Values from Integrated Images of Varian VitalBeam LINAC

Md. Motiur Rahman, MSc ^α, Md Fajle Rabby, MSc ^σ, Mahmuda Akter, MSc ^ρ, Rubel Ahmed, MSc ^ω, MMH Bhuiyan, PhD [¥] & MKA Khan, PhD [§]

Abstract- Modern dynamic radiotherapy techniques require more precision and need routine checking. However, presently available methods for Dosimetric Leaf Gap (DLG) and MLC transmission factor are highly time-consuming, so they are not feasible for busy radiotherapy centers. This analytical and observational study tried to determine the most straightforward way of simultaneously determining the transmission and DLG in the shortest time.

We measured all data at 5cm depth using a Varian VitalBeam LINAC, newly installed at TMSS Cancer Center, Bogura, Bangladesh. We used three significant pieces of equipment in our experiment: an integrated Electronics Portal Imaging Device (EPID), a solid water phantom and a farmer-type ion chamber (Model: IBA FC65-P). The Eclipse™ TPS was also used to make the QA plan and to analyze the images.

As per Varian machine recommendation, the transmission factor and DLG will be less than 2% and 2mm, respectively. In our measurement, using a Farmer-type ion chamber, we got the value of transmission factor of 1.46% and 1.69% and DLG of 0.98 mm and 1.13 mm for 6MV and 10MV photons, respectively. Using EPID a-Si1200, we got the transmission of 1.23% and 1.63% and DLG of 0.85 mm and 1.08 mm for 6MV and 10MV photons, respectively.

MLC transmission is in good agreement with ion chamber-based dosimetry with established data. It is a little lower for the 6MV photon EPID-based result, that is, maybe for the inhomogeneity characteristics of the photon fluence in low energies and negligible. For 10MV or higher energy photons, it is almost similar.

Keywords: *electronic portal imaging device (EPID), VMAT, dosimetric leaf gap (DLG), MLC transmission factor, calibration unit (CU).*

I. INTRODUCTION

Cancerous tumors are treated with radiotherapy by a specific dose of radiation. It is impossible for 100% of the supplied radiation to be deposited in the tumor due to the physics principles governing radiation dose deposition in a medium. Therefore, radiotherapy aims to treat cancer with a therapeutic dose while keeping the amount to the nearby healthy tissues within clinically tolerable bounds. Target localization and organ-at-risk (OAR) sparing are being improved by ongoing research and development focusing on using fewer resources. Volumetric Modulated Arc Therapy (VMAT), commonly administered using a linear accelerator, was implemented, significantly advancing in the past ten years [1]. An intensity-modulated radiotherapy (IMRT) method involves dynamically adjusting the radiotherapy treatment beam aperture to create a final beam of varying intensity. This technique can be done for several beams at different gantry angles, resulting in a dose distribution throughout the patient that better adheres to the treatment goal (than a static beam) and better spares nearby OARs. Modern IMRT requires inverse planning techniques since they automatically tune dose distributions by adjusting the photon fluence in the radiation fields [2].

IMRT fields are delivered using MLCs that move while the beam is offered to change the beam aperture's shape continuously. With the MLC motions, the LINAC's dose rate is coordinated. The MLC movements and LINAC dose rate are coordinated to provide the necessary two-dimensional beam intensity fluence. Karl Otto first developed VMAT, which more recently included the IMRT principles (2008). VMAT uses a continuous rotating gantry arc for delivery instead of IMRT, which uses a series of discrete fixed gantry angles because the MLC and dose rate are regulated. The VMAT approach alters LINAC's requirements to give the treatment. The LINAC's performance is under additional stress by these requirements, which include changing gantry speed, gantry angle-dependent dose rate modulation, and more complex MLC motions [2]. As a result, VMAT-specific QA systems must be created to check that the planned dose distributions match

Corresponding Author α: Department of Physics, Jagannath University, Dhaka, Bangladesh. e-mail: motiur.delta@gmail.com

Author §: Department of Physics, Jagannath University, Dhaka, Bangladesh.

Author σ ρ ω: Department of Radiation Oncology, TMSS Cancer Center (TCC), Bogura, Bangladesh.

Author ¥: Bangladesh Atomic Energy Commission (BAEC), Atomic Energy Research Establishment (AERE), Bangladesh.

those that were delivered and to assure delivery that is dependable, stable, and reproducible [2, 3]. During delivery, primary control is dictated by the gantry speed. The large mass of the treatment head makes this the most challenging component to modulate and control rapidly and accurately. When less than approximately 1.8 MU/deg is required, the gantry will move at maximum speed, but the dose rate will be dropped below 600 MU/min. When a more significant MU/deg rate is delivered, the maximum dose rate will be applied, and the gantry speed will slow down [4]. LINAC Quality Assurance (QA) testing is typical practice in radiation departments for guaranteeing LINAC performance. LINAC QA procedures typically rely on established best practice guidelines. The American Association of Physicists in Medicine (AAPM) TG-142 report [5] and AAPM Medical Physics Practice Guideline 8(a) are recent examples of such protocols [6]. The AAPM released guidelines for the delivery, treatment planning, and clinical application of IMRT in 2003 [7]. The AAPM released two task group reports in 2009 pertinent to IMRT and VMAT QA. The first, AAPM TG-142 [8], offered overarching guidelines for LINAC quality assurance [9].

Modern radiotherapy system is very sophisticated and requires quality assurance randomly. Nevertheless, due to the enormous patient load in a center, physicists and dosimetrists cannot set up QA equipment for daily checking of doses and machine parameters. So it required a quick setup system for equipment, essential parameters checkups, and patient plan verification. In 1990, a radiotherapy machine company introduced an Electronic Imaging system for checkup patients positioning [18]. After an era, they developed Electronics Imaging System called EPID. Modern EPID systems have an amorphous silicon-based detector for the patient imaging system, radiotherapy plan verification systems, and machine-specific QA systems. Task Group-58 (AAPM) published a report where they informed details use of EPID.

The goals of this research work are:

1. Calculation of the Transmission Factor for specific field size and DLG using conventional and EPID-based observation.
2. Comparison of EPID-based results with other protocols and institutional standards.

a) *MLC Transmission*

A radiation measurement has been performed with open and closed MLC for a 10x10cm² field at 5 cm depth, SSD = 95cm; the ratio of these measurements is the transmission factor. We made the appropriate position of the slabs of solid water phantom with the dedicated hole for the Iso-Center above 5 cm of thickness to consider backscatter. A Farmer-type chamber was fixed in the solid phantom dedicated hole, and the cable of the chamber was set on the couch. The solid water phantom was aligned and made centered using the field light of a 30x30cm² field. We mounted slabs for a thickness of 5 cm (chosen depth for the measurement) on the slab housing the detector. We set the SSD at 95cm, and the chamber position was in SAD at 100 cm. We took data in block field size using Leaf Bank A and B. In QA mode, we opened the TPS plan, which we had prepared previously and took data for MLC Bank A (R_{TA}) and B (R_{TB}), respectively.

By the equitation below, the transmission factor was determined using EPID. In that case, SAD was fixed at 100 cm or SSD at 95 cm from the EPID with a 5cm build-up.

$$\text{Transmission Factor, } R_T = \frac{R_{TA} + R_{TB}}{R_{Open}} \text{ ----- (1)}$$

b) *Dosimetric Leaf Gap (DLG)*

Due to the round shape of the leaf edge and the use of the leaves in a dynamic way, a dosimetric gap is created between them for the movement of the leaves during IMRT and VMAT treatment. We will quantify this gap using EPID in this research. A pictorial representation of transmission through the rounded end of the MLC leaf is shown in Figure 1, illustrating that both the optical field size and DLG constitute a radiation field [10].

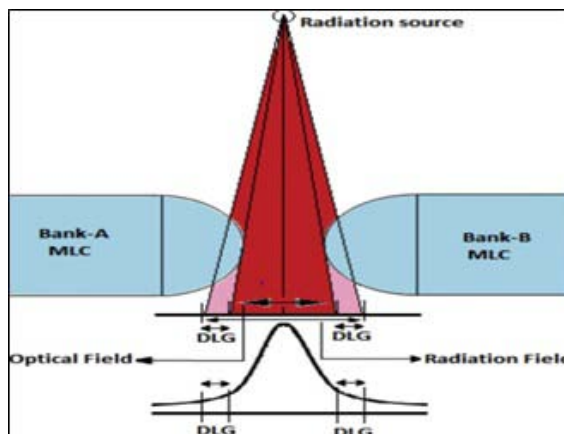


Figure 1: Transmission through the rounded-end of MLC leaf illustrating that both the optical field size and DLG constitute a radiation field [10].

Linear regression was performed using the acquired dose values and the related gap widths to evaluate the dynamic MLC fields with gap widths ranging from 0 to 20 mm. The intercept of the regression line was the DLG.

We continued the remaining fields for the preliminary plan in QA mode using the same experimental configuration for the MLC transmission: 7 fields with various gap sizes (2, 4, 6, 10, 14, 16, and 20 mm, respectively). The dose values from the electrometer display were read and recorded in an Excel file for each field. Each value was corrected while taking the RT contribution of the transmitted doses. Then we performed linear regression with the computed $R_{g,T}$ and the associated gap widths. The intercept of the linear extrapolation is the DLG (dose value corresponding to gap width = 0 mm). We measured the reading from the moving gap (R_g). We used 2 to 20 mm moving gap fields.

$$R_{g,T} = R_T \left(1 - \frac{R_g}{120}\right) \dots\dots\dots (2)$$

We calculated the corrected gap reading for each gap, g , which is defined as

$$R_g = R_g - R_{g,T} \dots\dots\dots (3)$$

II. MATERIALS AND METHOD

The tools and equipment used in this study: integrated Electronic Portal Imaging Device (EPID), Farmer-Type Ionization Chamber, Electrometer, Eclipse TPS Version 16.0.1 software.

a) *Electronic Portal Imaging Device (EPID)*

A 2D radiation detector integrated with the LINAC and used as a detector for both LINAC and patient-specific QA for IMRT/VMAT is called an EPID. Every time a patient is treated, the EPID is intended to assess their alignment with the radiation field [16]. Amorphous silicon-based active matrix flat panels are the now-standard EPID type (a-Si). In a 2D array, each photodiode is a single pixel that transforms incident light into an electric charge that a transistor uses to regulate signal reading [11].

Amorphous silicon EPID typically has thousands of faulty pixels (1%) in addition to the dark and flood field calibrations because of manufacturing restrictions [12]. These are adjusted by giving them the average value of the nearby pixels. Lastly, the EPID image grey scale is calibrated to LINAC Monitor Units under reference conditions for Varian patient-specific QA applications like Portal Dosimetry. The use of the Calibration Units (CU) calibration, also referred to as the dosimetry calibration on the VitalBeam LINAC, is accomplished by using the mean grey scale of an EPID image with a Region-of-Interest mean value at the central axis of 100MU under reference conditions and a designated CU value to provide a correction factor to

the grey scale for the following reasons: subsequent images.

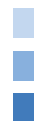For use in dynamic treatments like IMRT and VMAT, the MLC has been the most often researched LINAC component with QA tests employing an EPID [13]. Other LINAC parts undergoing EPID testing include physical and dynamic wedges [14], gantry angle, asymmetric jaw alignment, and x-ray.

Using the Eclipse TPS, a QA plan was created to determine the transmission factor and the DLG. According to that plan, radiation was exposed to the EPID in QA mode. The MLC transmission and DLG of the machine were determined by analyzing the EPID based predicted integrated images. After the analysis, the information was processed, and the acquired data from the study were compared to VARIAN Machine Protocol and with some published data from various renowned international journals.

This thesis aims to determine how easily we can perform LINAC machine quality assurance using EPID or other array system diode-based QA devices. We tried to evaluate the DLG using EPID. The EPID system must first be configured to make it functional and usable. In the VARIAN VitalBeam Machine, the Portal Dose Image Prediction (PDIP) algorithm is usually used. Most radiotherapy centers perform Anisotropic Analytical Algorithms (AAA) to calculate the volume dose in the planning system of the LINAC machine. Some centers also use the AcurosXB algorithm. After installing a new LINAC machine, the acquired depth dose and beam profile data have been inserted into the TPS to configure it, making the machine fully commissioned and prepared for further treatment. The same data are also used to configure the PDIP.

b) *Farmer-Type Ionization Chamber*

The standard for output measurement is placing an ionization chamber like IBA FC65-P 0.6cc Farmer type chamber, positioned at 5 cm depth in a solid water phantom at 100 cm SSD. A Strontium source was used to examine the chamber response's consistency and to compare it to other Farmer-type chamber responses. The chamber response was then tracked back to the secondary standards laboratory. A solid water phantom setup with a Farmer-type ionization chamber is shown in Figure 2.



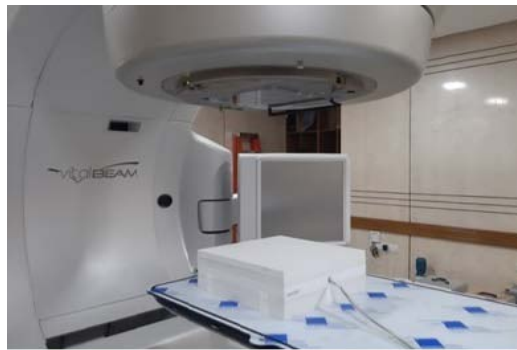

Figure 2: Solid water phantom setup with Farmer-type ionization chamber.

c) *The Linear Regression*

Linear regression is a very suitable tool for predictive analysis. It is generally used for forecasting an effect, forecasting a trend and determining the predictor's strength linearly. The formula defines the simplest form of the equation of linear regression

$$y = bx + c \dots \dots \dots (4)$$

Where,

- y = the estimated score of the dependent variable,
- c = constant,
- b = regression co-efficient and

x = the independent variable score.

d) *Transmission and DLG Measurement from Ionization Chamber Based Data*

Measurement data for MLC transmission and DLG were tabulated in Table 1 using a standard 10x10 cm² field size & 100 MU delivered for each energy and similar dose rates. SSD and SDD were 95 cm and 100 cm, respectively. IBA FC65-P ionization chamber and IBA Dose-1 electrometer were used. All of the data reading units were in nC charge.

Table 1: Ionization Chamber-Based Measurements for MLC Transmission and DLG. All of the data reading units are in nC charge reading. (R_{open} = Open Field Charge Reading with Jaw Setting 10x10cm² and MLC fully open, R_{T, A} = Transmission Reading for MLC Bank-A and R_{T, B} = Transmission Reading for MLC Bank-B and Gap = MLC Gap with Jaw Setting 10x10cm²)

Energy	R _{Open}	R _{T, A}	R _{T, B}	Gap 2mm	Gap 4mm	Gap 6mm	Gap 10mm	Gap 14mm	Gap 16mm	Gap 20 mm
6 MV	1.865	0.0272	0.0272	0.0731	0.1038	0.1339	0.1950	0.2562	0.2870	0.3481
10 MV	2.040	0.0348	0.0346	0.0874	0.1209	0.1535	0.2204	0.2871	0.3207	0.3874

A graphical representation for DLG using solid water phantom with Farmer-type ionization chamber for 6MV and 10MV photons is shown in Figure 3 and Figure 4, respectively.

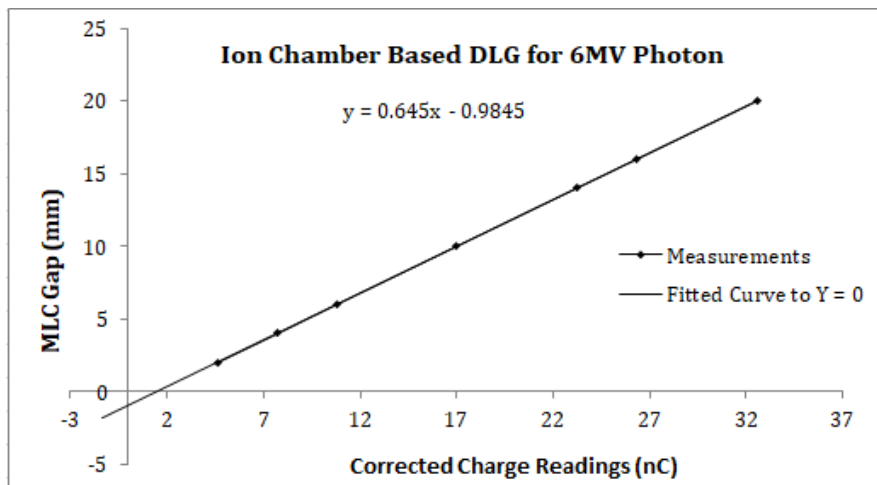


Figure 3: Graph for DLG calculation using solid water phantom with Farmer type ionization chamber for 6MV photon

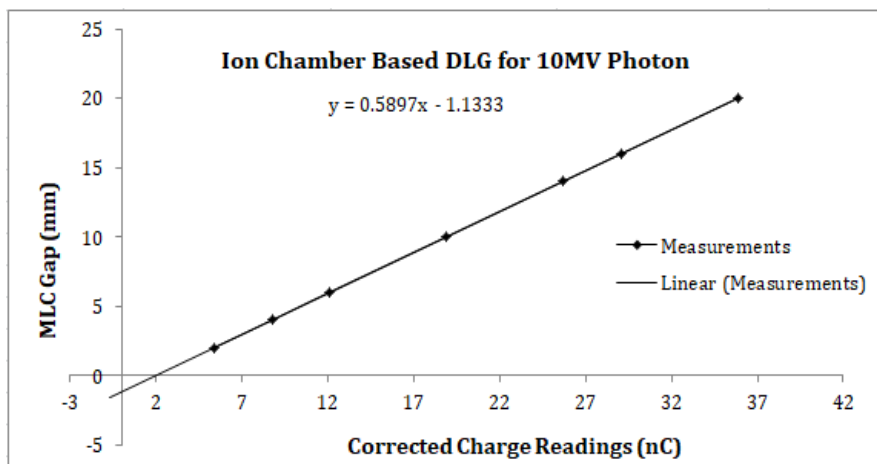


Figure 4: Graph for DLG calculation using solid water phantom with Farmer type ionization chamber for 10MV photon

We fitted a linear function $g(Rg') = aRg' + c$ to points given by gap size g and corrected gap reading Rg' . We extrapolated the curve linearly to zero and found the intercept of the fitted function (c). The absolute value of c is the DLG.

e) *Transmission and DLG Measurement from EPID-Based Data*

To perform any EPID-based QA-related study, first, it is necessary to calibrate the electronic portal imaging system. We calibrated EPID response to be $100\text{MU} \approx 1\text{CU}$. Using the PDIP technique, the beam exposer was analyzed after exposing the fields on the

EPID. We utilized the iso-center CU value from our exposer field image analysis to estimate the GAP and transmission factor.

The EPID Based Measurement data for MLC transmission and DLG were given in Table 2 using a 3.8 cm solid water phantom (actually 5cm, because there is an integrated build-up of 1.2cm on the EPID) placed on top of the EPID. Measurements were taken using a standard $10 \times 10 \text{ cm}^2$ field size & 100 MU was delivered for each energy. SSD, SDD and dose rates were identical to the ion chamber-based experimental setup. All of the data reading units are in CU.

Table 2: EPID-based measurements for MLC transmission and DLG using solid water phantom placed on the EPID. All of the data reading units are in CU. (R_{open} = Open Field CU Reading with Jaw Setting $10 \times 10 \text{ cm}^2$ and fully open MLC; $R_{T,A}$ = Transmission Reading for MLC Bank-A; $R_{T,B}$ = Transmission Reading for MLC Bank-B and Gap = MLC Gap with Jaw Setting $10 \times 10 \text{ cm}^2$)

Energy	R_{Open}	$R_{T,A}$	$R_{T,B}$	Gap 2mm	Gap 4mm	Gap 6mm	Gap 10mm	Gap 14mm	Gap 16mm	Gap 20 mm
6 MV	0.972	0.012	0.012	0.035	0.051	0.066	0.098	0.130	0.146	0.178
10 MV	1.011	0.017	0.016	0.042	0.059	0.075	0.108	0.141	0.158	0.191

A graphical representation for DLG for 6MV and 10MV photons using solid water phantom with EPID is shown in Figure 5 and Figure 6, respectively. We similarly obtained the DLG to ion chamber-based curve fitting.

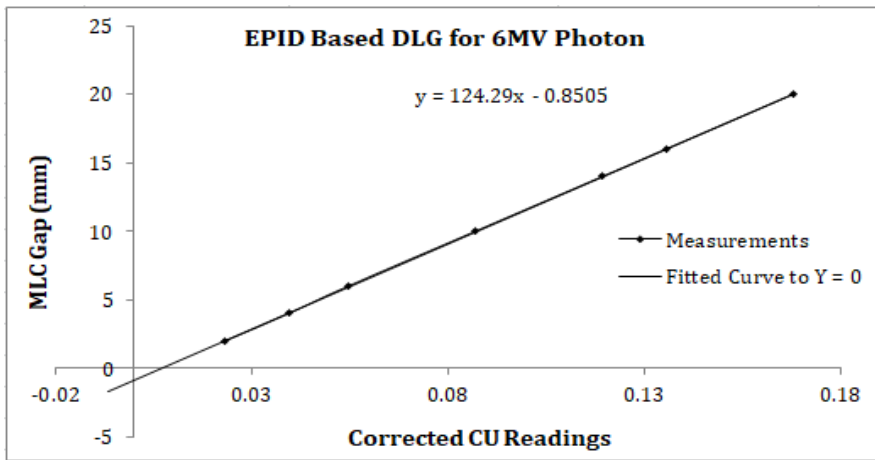


Figure 5: Graph for DLG calculation for 6MV photon using solid water phantom with EPID.

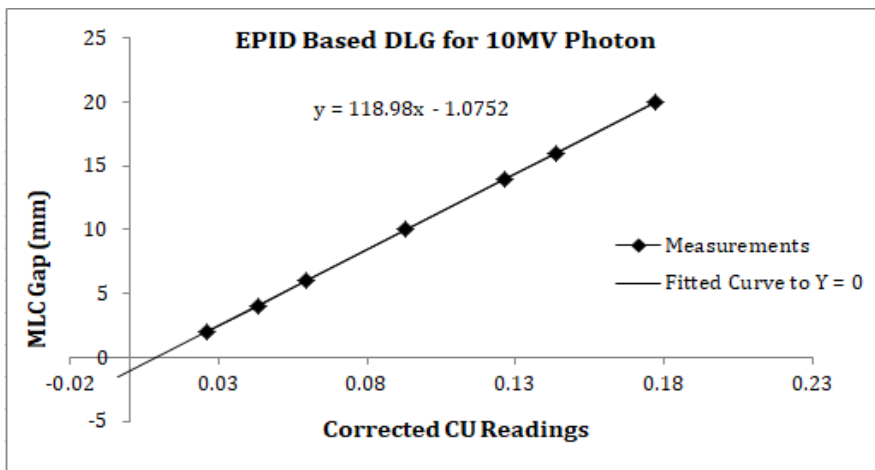


Figure 6: Graph for DLG calculation for 10MV photon using solid water phantom with EPID.

The CU data collection procedure for the open field iso-center is shown in Figure 7 and Figure 8 for 6MV and 10MV photons, respectively. The CU data for

the other jaw and MLC settings were extracted similarly from the portal images.

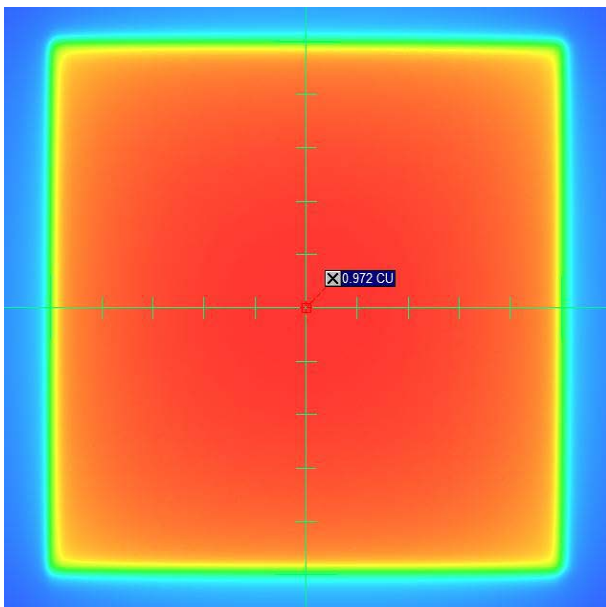


Figure 7: The CU data collection procedure for the open field iso-center for 6MV photon

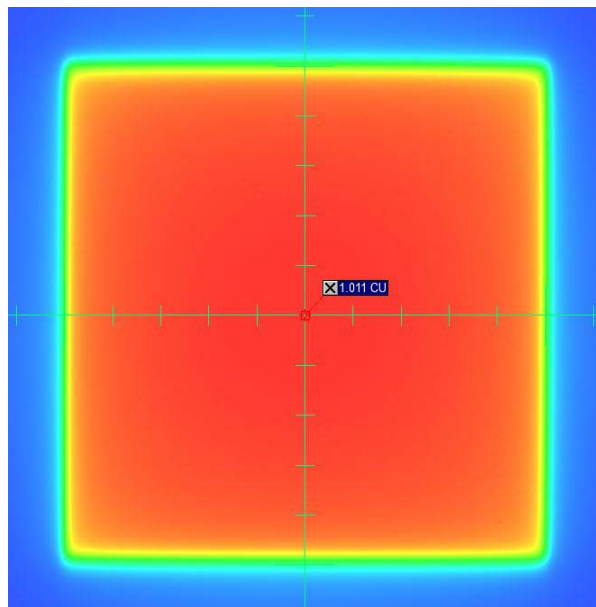


Figure 8: The CU data collection procedure for the open field iso-center for 10MV photon



III. RESULTS AND DISCUSSION

Transmission radiation through the collimator and DLG are essential functions in modern radiotherapy dose calculation. In modern radiotherapy machines, a multi-leaf collimator (MLC) (mostly 120 leaves) is used, and this device (MLC) is used as an organ-at-risk (OAR) saving tool. According to the radiotherapy goal, a maximum dose should be delivered to the tumour and a minimum dose to OAR [15]. That is why MLC is used in radiotherapy. We can determine the transmission and DLG using a 3D or 1D water phantom, but it takes much time to prepare and set it up. So, it is not easy in busy centers to check transmission and DLG routinely or quarterly in a year. As per Varian machine recommendation, the transmission factor will be less than 2%, and DLG will be less than 2mm. IMRT or VMAT treatment modalities were extensively developed after the discovery of MLC.

This study investigated the DLG values using the FC65-P ionization chamber with a 5cm thick solid water phantom and VARIAN MV EPID 1200aSi with a similar build-up. Depending on the value of DLG, it may cause errors in dose calculation for a Millennium and High-definition MLC [10]. This parameter accounts for partial transmission through the end of the rounded leaf. It is designed for patients treated with rounded-end MLC to improve dose calculation accuracy in the advanced high-precision radiotherapy technique. Various MLC parameters must be evaluated and verified while incorporating the high-end technique as IMRT/VMAT in Treatment Planning System (TPS) [10].

In comparison with the publication of a multi-institutional survey in Japan entitled "Inter-unit variability

of multi-leaf collimator parameters for IMRT and VMAT treatment planning: a multi-institutional survey"[17]. Where they got the value of DLG for the TrueBeam machine is 1.16 ± 0.22 mm for 6MV and 1.32 ± 0.21 mm for 10 MV Photon Beam. In our measurement, we got the DLG value of 0.98mm for 6MV and 1.13mm for 10MV photon beams using a Farmer-type IBA FC65-P ionchamber. But using EPID 1200aSi, we got the result 0.85mm for 6MV and 1.08mm for 10MV photon beams.

Comparing the ionization chamber and EPID-based dosimetry result, we observed that DLG deviation is 0.13 mm for 6MV and 0.05mm for 10MV photon beam. Moreover, transmission factor deviation is 0.23% & 0.06%, respectively, for 6MV and 10MV photon beams. In the multi-institutional survey [17], the value of MLC transmission for TrueBeam Machine was $1.50\% \pm 0.05\%$ for 6MV and $1.72\% \pm 0.06\%$ for 10MV photon energy. In our measurement, we got the value of 1.46% for 6MV and 1.69% for 10MV using a Farmer-type IBA FC65-P ionchamber. But using EPID 1200aSi, we got the result 1.23% for 6MV and 1.63% for 10MV photon beam. The published data [17] & our measurement for MLC transmission are in good agreement with ion chamber-based dosimetry, and for EPID-based result, it is a little lower for 6MV photon, that is, maybe for the inhomogeneity characteristics of the photon fluence in low energies and negligible, and for 10MV or higher energy photon, it is almost similar. The results for transmission factor and DLG for both the ionization chamber and EPID-based dosimetry are given in Table 3.

Table 3: The results for transmission factor and DLG for both ionization chamber and EPID-based dosimetry.

Energy	DLG with Ion Chamber (mm)	DLG with EPID (mm)	Transmission Factor with Ion Chamber	Transmission Factor with EPID
6 MV	0.98	0.85	1.46%	1.23%
10 MV	1.13	1.08	1.70%	1.63%

IV. CONCLUSION

In conclusion, the deviation between phantom and EPID-based DLG and transmission factor will not significantly affect actual radiotherapy patient treatment. So, we can use EPID-based DLG and transmission factor. However, the pre-requisition of EPID will be fully configured before the data acquisition, and the Portal Dose Image Prediction (PDIP) algorithm will be fully configured. Then, we can determine the DLG and transmission factor with just a few shots. We hope that more research on these topics can be conducted in the future with more precise experimental results.

ACKNOWLEDGEMENTS

We sincerely thank TMSS Medical College & Rafatullah Community Hospital and TMSS Cancer Center for allowing us to use their radiotherapy and dosimetry equipment. A sincere gratitude goes to the chairman and respected teachers of Jagannath University's Physics Department for their encouragement and collaboration on this research. Thanks are also due to Professor Dr Hosne-Ara Begum, Executive Director, TMSS; Dr Md. Matiur Rahman, Deputy Executive Director-2, TMSS; and Professor Dr AKM Ahsan Habib, Project Director & Head of the Radiation Oncology Department, TMSS Cancer Center, for permitting us to use all their facilities.

Compliance with Ethical Standards and Conflict of Interest

No conflict of interest is declared in this research article, and no organization grant for this study project.

REFERENCES RÉFÉRENCES REFERENCIAS

1. Adamson J, Wu Q. Independent verification of gantry angle for pre-treatment VMAT QA using EPID. *Physics in Medicine & Biology*. 2012 Sep 25; 57(20): 6587.10.1088/0031-9155/57/20/6587
2. Fuangrod T, Woodruff HC, Van Uytven E, McCurdy BM, Kuncic Z, O'Connor DJ, Greer PB. A system for EPID-based real-time treatment delivery verification during dynamic IMRT treatment. *Medical physics*. 2013 Sep; 40(9): 09190710.1118/1.4817484
3. Otto K. Volumetric modulated arc therapy: IMRT in a single gantry arc. *Medical physics*. 2008 Jan; 35(1): 310-7.10.1118/1.2818738
4. Nicolini G, Clivio A, Cozzi L, Fogliata A, Vanetti E. On the impact of dose rate variation upon RapidArc® implementation of volumetric modulated arc therapy. *Medical physics*. 2011 Jan; 38(1): 264-71.10.1118/1.3528214
5. Klein EE, Hanley J, Bayouth J, Yin FF, Simon W, Dresser S, Serago C, Aguirre F, Ma L, Arjomandy B, Liu C. Task Group 142 report: Quality assurance of medical accelerators a. *Medical physics*. 2009 Sep; 36(9Part1): 4197-212.10.1118/1.3190392
6. Smith K, Balter P, Duhon J, White Jr GA, Vassy Jr DL, Miller RA, Serago CF, Fairobent LA. AAPM Medical Physics Practice Guideline 8. a.: linear accelerator performance tests. *Journal of applied clinical medical physics*. 2017 Jul; 18(4): 23-39.10.1002/acm2.12080
7. Ezzell GA, Galvin JM, Low D, Palta JR, Rosen I, Sharpe MB, Xia P, Xiao Y, Xing L, Yu CX. Guidance document on delivery, treatment planning, and clinical implementation of IMRT: report of the IMRT Subcommittee of the AAPM Radiation Therapy Committee. *Medical physics*. 2003 Aug; 30(8): 2089-115.10.1118/1.1591194
8. Ezzell GA, Burmeister JW, Dogan N, LoSasso TJ, Mechalakos JG, Mihailidis D, Molineu A, Palta JR, Ramsey CR, Salter BJ, Shi J. IMRT commissioning: multiple institution planning and dosimetry comparisons, a report from AAPM Task Group 119. *Medical physics*. 2009 Nov; 36(11): 5359-73. DOI: 10.1118/1.3238104
9. Klein EE, Hanley J, Bayouth J, Yin FF, Simon W, Dresser S, Serago C, Aguirre F, Ma L, Arjomandy B, Liu C. Task Group 142 report: Quality assurance of medical accelerators a. *Medical physics*. 2009 Sep; 36(9Part1): 4197-212.10.1118/1.3190392
10. Shende R, Patel G. Validation of Dosimetric Leaf Gap (DLG) prior to its implementation in Treatment Planning System (TPS): TrueBeam™ millennium 120 leaf MLC. *Reports of Practical Oncology and Radiotherapy*. 2017; 22(6): 485-94. 10.1016/j.rpor.2017.09.001
11. McCurdy BM, Luchka K, Pistorius S. Dosimetric investigation and portal dose image prediction using an amorphous silicon electronic portal imaging device. *Medical physics*. 2001 Jun; 28(6): 911-24. 10.1118/1.1374244
12. Varian Medical Systems. Image Acquisition System-3 Reference Guide. Varian Associates Inc. Oncology Systems, Palo Alto, CA. 2011.
13. Vieira SC, Dirx ML, Pasma KL, Heijmen BJ. Fast and accurate leaf verification for dynamic multileaf collimation using an electronic portal imaging device. *Medical physics*. 2002 Sep; 29(9): 2034-40.10.1118/1.1501141
14. Pasma KL, Kroonwijk M, De Boer JC, Visser AG, Heijmen BJ. Accurate portal dose measurement with a fluoroscopic electronic portal imaging device (EPID) for open and wedged beams and dynamic multileaf collimation. *Physics in Medicine & Biology*. 1998 Aug 1; 43(8): 2047.10.1088/0031-9155/43/8/004
15. Chavaudra J, Bridier A. Definition of volumes in external radiotherapy: ICRU reports 50 and 62. *Cancer radiotherapie: journal de la Societe francaise de radiotherapie oncologique*. 2001 Oct 1; 5(5): 472-8.10.1016/s1278-3218(01)00117-2
16. Van Dyk J. *Advances in modern radiation therapy*. Medical Physics Pub. Corp. 2005. https://medicalphysics.org/documents/VanDyk1_Ch8.pdf
17. Isono M, Akino Y, Mizuno H, et al. Inter-unit variability of multi-leaf collimator parameters for IMRT and VMAT treatment planning: a multi-institutional survey. *Journal of radiation research*. 2020 Mar; 61(2): 307-13.10.1093
18. Rahman MM, Shamsuzzaman M, Bhuiyan MM. Development of a spreadsheet for rapid assessment of therapeutic radiation dose delivery with electron and photon beams at various energies. *J Cancer Prev Curr Res*. 2022; 13(1): 8-12. DOI: 10.15406/jcpcr.2022.13.00479
19. Rahman M, Shamsuzzaman M, et al. Dosimetric characterization of medical linear accelerator Photon and Electron beams for the treatment accuracy of cancer patients. *World Journal of Advanced Engineering Technology and Sciences*. 2021; 3(01): 041-59. DOI: 10.30574/wjaets.2021.3.1.0046



GLOBAL JOURNAL OF MEDICAL RESEARCH: D
RADIOLOGY, DIAGNOSTIC AND INSTRUMENTATION
Volume 23 Issue 1 Version 1.0 Year 2023
Type: Double Blind Peer Reviewed International Research Journal
Publisher: Global Journals
Online ISSN: 2249-4618 & Print ISSN: 0975-5888

Acute Generalized Peritonitis due to Peritoneal Hydatid Cyst Rupture By Outznit Mustapha, Lina Belkouchi, Laamrani F.Z & Jroundi Laila

Summary- Peritoneal hydatidosis is a rare and poorly known hydatid disease. Acute cyst rupture into the peritoneal cavity is one of its complications. We report a clinical case of a 25-year-old patient admitted to the emergency department for acute abdominal pain, the final diagnosis was acute peritonitis caused by the rupture of hydatid cyst into the peritoneal cavity associated with hepatic hydatidosis.

Keywords: peritoneal hydatidosis, peritonitis, cyst, acute abdomen.

GJMR-D Classification: DDC Code: 616.362 LCC Code: RC846



Strictly as per the compliance and regulations of:



© 2023. Outznit Mustapha, Lina Belkouchi, Laamrani F.Z & Jroundi Laila. This is a research/review paper, distributed under the terms of the Creative Commons Attribution-Noncommercial 3.0 Unported License (<http://creativecommons.org/licenses/by-nc/3.0/>), permitting all non-commercial use, distribution, and reproduction in any medium, provided the original work is properly cited.

Acute Generalized Peritonitis due to Peritoneal Hydatid Cyst Rupture

Péritonite Aigue Généralisée Par Rupture D'un Kyste Hydatique Péritonéal

Outznit Mustapha ^α, Lina Belkouchi ^σ, Laamrani F.Z ^ρ & Jroundi Laila ^ω

Résumé- L'hydatidose péritonéale est une localisation rare et peu connue de la maladie hydatique. Parmi ses complications la rupture brutale d'un kyste hydatique dans la cavité péritonéale. Nous rapportons le cas d'un patient âgé de 25 ans admis aux urgences pour l'exploration d'un abdomen aigu dont le diagnostic final est une péritonite aigue généralisée par rupture d'un kyste hydatique intra-péritonéal associée à une hydatidose hépatique.

Mots clés: hydatidose péritonéale, péritonite, kyste, abdomen aigu.

Summary- Peritoneal hydatidosis is a rare and poorly known hydatid disease. Acute cyst rupture into the peritoneal cavity is one of its complications. We report a clinical case of a 25-year-old patient admitted to the emergency department for acute abdominal pain, the final diagnosis was acute peritonitis caused by the rupture of hydatid cyst into the peritoneal cavity associated with hepatic hydatidosis.

Keywords: peritoneal hydatidosis, peritonitis, cyst, acute abdomen.

I. INTRODUCTION

La maladie hydatique est une anthro-zoonose qui sévit à l'état endémique en région méditerranéenne, le péritoine au même titre que d'autres organes comme le foie peut être une localisation rare et grave de cette affection. L'objectif de cet article est de présenter, à travers un cas clinique d'abdomen aigu, les éléments sémiologiques d'une hydatidose péritonéale dans sa forme compliquée de rupture.

II. OBSERVATION CLINIQUE

Il s'agit d'un jeune patient âgé de 25 ans, sans antécédents particuliers, qui consulte au service des urgences pour l'installation brutale d'une douleur abdominale généralisée après effort physique. L'examen clinique trouve un patient conscient, apyrétique et légèrement tachycarde. La palpation de l'abdomen objective une contracture généralisée avec une sensibilité plus marquée au niveau de la fosse iliaque gauche.

Une tomodynamométrie abdomino-pelvienne est réalisée sans et après injection de produit de contraste. Cette dernière, montre au niveau du foie droit

de multiples formations kystiques, à contenu liquidien pur ou cloisonné, bien circonscrites, confluentes, à paroi épaissie rehaussées en périphérie après injection de produit de contraste en rapport avec des kystes hydatiques hépatiques de taille et de type variable.

Il s'y associe également au niveau pelvien deux kystes hydatiques intra-péritonéaux, le premier est multi vésiculaire et le deuxième sus et latéro-vésicale gauche à paroi affaissée, discontinue associée à un épanchement péritonéal témoignant sa rupture dans la cavité péritonéale.

Le diagnostic de péritonite aigue généralisée par rupture d'un kyste hydatique intra-péritonéal associée à une hydatidose hépatique est retenu.

III. DISCUSSION

Le kyste hydatique est dû au développement de la forme larvaire du tænia du chien appelé *Echinococcus granulosus*. C'est une zoonose cosmopolite, endémique dans les pays du Maghreb, l'Afrique de l'Est et l'Amérique du Sud. La contamination de l'homme se fait dans la majorité des cas après une ingestion d'aliments souillés par les fèces du chien infesté [1].

L'hydatidose péritonéale représente entre 5 et 16 % des hydatidoses [2]. Elle peut être primitive, par contamination hématogène. Elle est le plus souvent secondaire à une rupture kystique (kyste hydatique hépatique fréquemment associé) ou à une contamination per opératoire.

La symptomatologie clinique est variable et non spécifique, parfois de découverte fortuite du au développement lent du kyste hydatique après contamination.

Elle peut se manifester par une douleur abdominale chronique, nausées, vomissements et anorexie. Les formes compliquées des kystes demeurent dans la compression des organes de voisinage, une hémorragie intra-kystique, surinfection et rarement une rupture intra ou extra-péritonéale [3].

La rupture du kyste hydatique peut être spontanée par augmentation de la pression intra-kystique ou post-traumatique. Elle met en jeu le pronostic vital du fait de l'état de choc anaphylactique qu'elle peut engendrer. Elle se manifeste par une douleur abdominale sévère, des vomissements, une

Corresponding Author α: Internat Hôpital Ibn Sina 40010 Rabat, Maroc.
e-mail: outznitmustapha@gmail.com

chute de la tension artérielle, une tachycardie voir des réactions allergiques [4].

Grace à l'imagerie médicale, le diagnostic de cette entité devient de plus en plus facile et rapide. L'échographie abdominale et la tomodensitométrie ont respectivement une sensibilité de 85% et 100% [5].

L'échographie abdominale est réalisée en première intention permettant ainsi de confirmer le diagnostic en précisant la localisation du kyste, le nombre et ses rapports anatomiques. Toute fois sa résolution spatiale est limitée comparativement à la tomodensitométrie qui permet une analyse plus précise de l'environnement du kyste [6].

Le traitement médical initial est basé sur les mesures de réanimation en cas de choc anaphylactique par l'administration des drogues vasoactives, remplissage et monitoring. Ensuite une toilette

péritonéale abondante est réalisée par le sérum physiologique avec aspiration. La technique chirurgicale de choix dans le contexte d'urgence est la résection du dôme saillant qui est une méthode facile et adaptée aux pays d'endémie [7].

IV. CONCLUSION

La rupture aigue d'un kyste hydatique dans la cavité péritonéale est un phénomène rare mettant en jeu le pronostic vital. Elle doit être toujours suspectée dans les pays d'hyper endémie hydatique. L'échographie et la tomodensitométrie permettent un diagnostic précoce de cette complication.

Déclarations des auteurs

Les auteurs déclarent ne pas avoir de conflit d'intérêt en relation avec cet article.

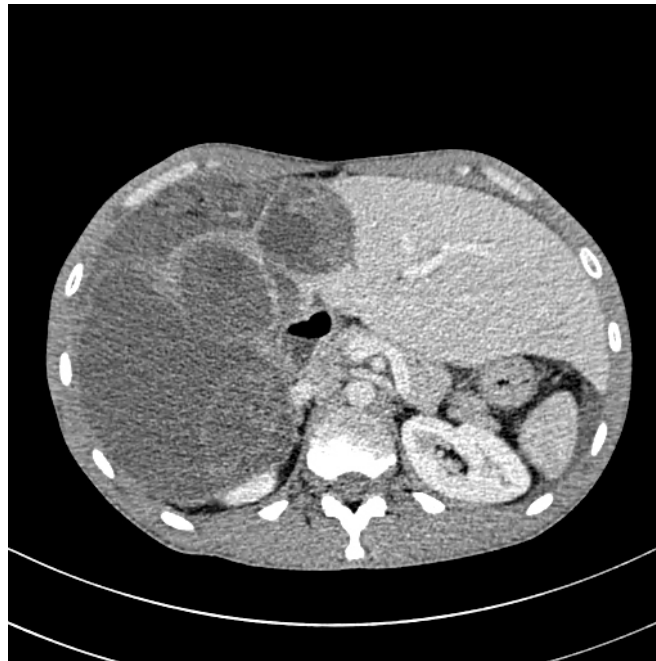

Figure 1A

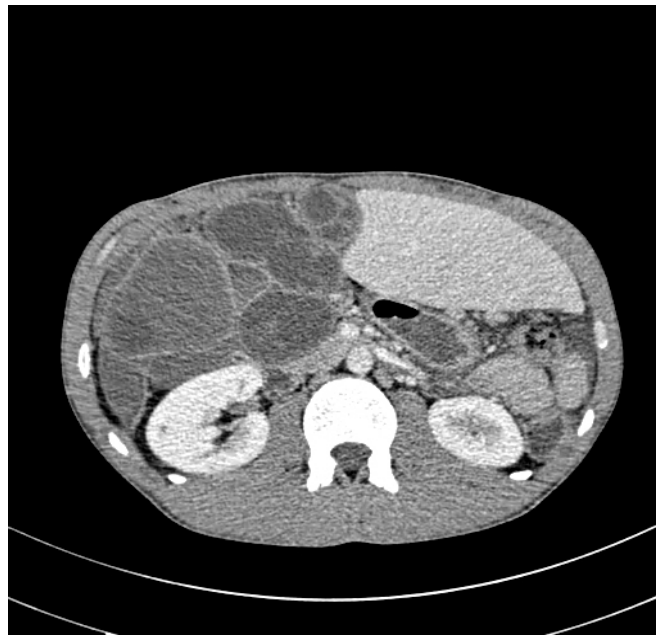


Figure 1B

Figure 1A et 1B: TDM abdominale en coupe axiale montrant la présence de multiples kystes hydatiques du foie droit.

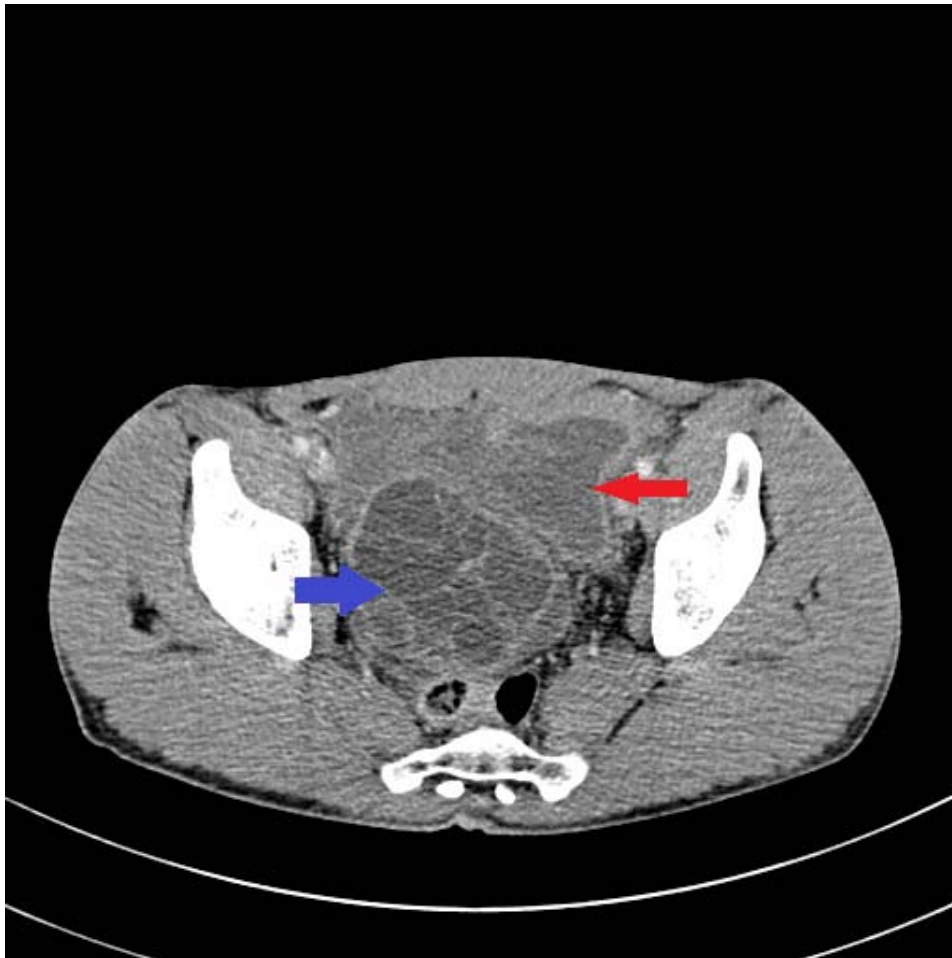

Figure 2A

Figure 2A: TDM pelvienne en coupe axiale montrant la présence d'un kyste hydatique multi vésiculaire (flèche bleue) et un autre sus et latéro-vésical gauche à paroi affaissée et discontinue (flèche rouge) associée à un épanchement péritonéal témoignant de sa rupture aigue.



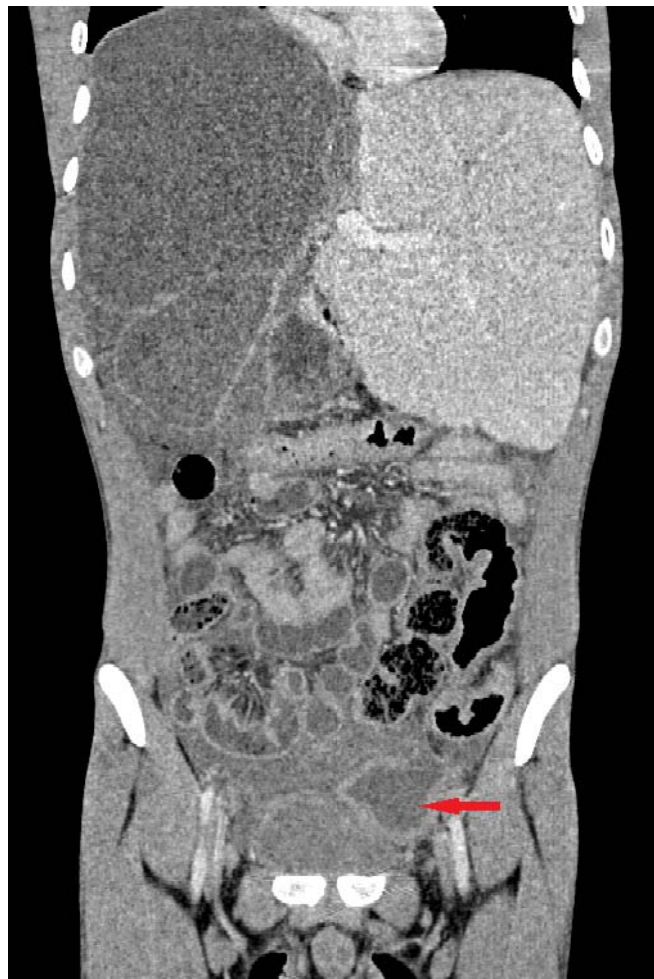

Figure 2B

Figure 2B: Reconstruction coronale.

REFERENCES RÉFÉRENCES REFERENCIAS

1. Séverine Thys^{1,2*}, Hamid Sahibi³, Sarah Gabriël⁴, Tarik Rahali⁵, Pierre Lefèvre⁶, Abdelkbir Rhaïem³, Tanguy Marcotty⁷, Marleen Boelaert¹ and Pierre Dorny^{8,2} Community perception and knowledge of cystic echinococcosis in the High Atlas Mountains, Morocco Thys et al. BMC Public Health (2019) 19:118 <https://doi.org/10.1186/s12889-018-6372-y>
2. Mejri, K. Arfaoui, M.F. Ayadi et al. This is what we call peritoneal hydatidosis. Int J Infect Dis (2020), <https://doi.org/10.1016/j.ijid.2020.05.028>
3. Maria João Amaral, Marco Serôdio, c Maria João Kocha Rui Almeida, José Carlos Campos, José Guilherme Tralhão, c, e. Ruptured Hemorrhagic Hepatic Cyst: An Unusual Case Report GE Port J Gastroenterol 2020; 27: 124–127, DOI: 10.1159/000502359
4. Akbulut S, Ozdemir F. Intraperitoneal rupture of the hydatid cyst: Four case reports and literature review. World J Hepatol 2019; 11(3): 318-329 <https://dx.doi.org/10.4254/wjh.v11.i3.318>
5. Sozuer E, Akyuz M, Akbulut S. Open surgery for hepatic hydatid disease. Int Surg 2014; 99: 764-769 DOI: 10.9738/INTSURG-D-14-00069.1]
6. H. Benhamiche, D. Sottier, M. Funes De La Vega, B. Cuisenier, N. Mejean, D. Krausé Hydatidose péritonéale secondaire à la rupture d'un kyste hydatique hépatique Journal de Radiologie Diagnostique et Interventionnelle, Volume 94, Issue 11, November 2013, Pages 1156-1159 <https://doi.org/10.1016/j.diii.2013.04.009>
7. Ch Kosmidis, C. Efthimiadis, G. Anthimidis, K. Vasileiadou, G. Koimtzis, I. Tzeveleki, T. Koletsa, J. Prousalidis, E. Fahantidis, G. Basdanis, A. Michalopoulos, I. Kesisoglou. Management of peritoneal hydatid cysts: A forty-year experience. Heliyon 4 (2018) e00994. doi: 10.1016/j.heliyon.2018. e00994



GLOBAL JOURNAL OF MEDICAL RESEARCH: D
RADIOLOGY, DIAGNOSTIC AND INSTRUMENTATION
Volume 23 Issue 1 Version 1.0 Year 2023
Type: Double Blind Peer Reviewed International Research Journal
Publisher: Global Journals
Online ISSN: 2249-4618 & Print ISSN: 0975-5888

The Comparison Study of Lung Computerized Tomography Severity Score and Vaccination Status in Covid-19 Patient's

By Dr. Rohith Sandesari, Dr. T Rajani & Dr. Jyostna Rani Y

Abstract- In the COVID-19 pandemic, HRCT chest is often used by clinician to determine extent of their lung involvement. The aim of this study is to assess the severity of lung involvement in confirmed/suspected COVID-19 patients and its correlation to vaccination status, with either COVISHIELD or COVAXIN, in a tertiary care center. This is a retrospective study, in which our data is analyzed from 1st April 2021 to 30th April 2021, to identify patients (>16 years) who had confirmed (positive RT-PCR or antigen test) and received a HRCT Chest within 1st week (Avg <3.5 days) of RT-PCR Positive test, to determine the extent of their lung involvement using the CT severity score (CT-SS). Patients were classified in 3 groups based on their vaccination status to determine its correlation with the CT-SS score: fully vaccinated (received 2 doses of vaccine), partially vaccinated (one dose of vaccine), and unvaccinated. Basic descriptive statistics, Student t test and ANOVA test were done using Epi-info 7.1 software M.S.Windows.

Keywords: COVID-19-Coronavirus 2019 or SARS-CoV2 infection; HRCT-high resolution computerized tomography; CT-SS-computerized tomography severity score; RT-PCR-reverse transcription polymerase chain reaction.

GJMR-D Classification: DDC Code: 616.912 LCC Code: RA644.S6



Strictly as per the compliance and regulations of:



The Comparison Study of Lung Computerized Tomography Severity Score and Vaccination Status in Covid-19 Patient's

Dr. Rohith Sandesari ^α, Dr. T Rajani ^σ & Dr. Jyostna Rani Y ^ρ

Abstract- In the COVID-19 pandemic, HRCT chest is often used by clinician to determine extent of their lung involvement. The aim of this study is to assess the severity of lung involvement in confirmed/suspected COVID-19 patients and its correlation to vaccination status, with either COVISHIELD or COVAXIN, in a tertiary care center. This is a retrospective study, in which our data is analyzed from 1st April 2021 to 30th April 2021, to identify patients (>16 years) who had confirmed (positive RT-PCR or antigen test) and received a HRCT Chest within 1st week (Avg <3.5 days) of RT-PCR Positive test, to determine the extent of their lung involvement using the CT severity score (CT-SS). Patients were classified in 3 groups based on their vaccination status to determine its correlation with the CT-SS score: fully vaccinated (received 2 doses of vaccine), partially vaccinated (one dose of vaccine), and unvaccinated. Basic descriptive statistics, Student t test and ANOVA test were done using Epi-info 7.1 software M.S.Windows. A total of n=175 patients (median age 51 years, 66.3% male; 33.7% female) of which 158 (90%) had confirmed COVID-19 positive RT-PCR and 17(10%) had disease with classic symptoms and rapid antigen test positive for COVID 19. Of the 175 patients 34 (19.4%) had complete vaccination, 63 (36%) had partial vaccination and 78(44.6%) had no vaccination. The CT severity score of the completely vaccinated patients was significantly lower (i.e., between 0 to 2), compared to partially vaccinated (i.e., between 2 to 18) & unvaccinated patients (i.e., between 2 to 23). The mean CT-SS of vaccinated, partially vaccinated & unvaccinated is 0.23 ± 0.11 , 6.98 ± 0.62 , & 11.46 ± 0.73 , respectively $p < 0.001$. A multivariate linear regression model showed that partial or fully vaccinated patient's had lower CT severity score compared to unvaccinated patients (adjusted R squared = 0.41). CT severity score in fully vaccinated patients is significantly lower compared to partially vaccinated or unvaccinated patients. Complete vaccination in patients could be critical in preventing severe lung disease. However, we found no significant difference in CT-SS of vaccinated patients who had taken either COVISHIELD or COVAXIN.

Keywords: COVID-19-Coronavirus 2019 or SARS-CoV2 infection; HRCT-high resolution computerized tomography; CT-SS-computerized tomography severity score; RT-PCR-reverse transcription polymerase chain reaction.

*Corresponding Author α: Resident (MD).
e-mail: sandesari001@gmail.com
Author σ: Associate Professor (MD).
Author ρ: Hod and Professor (DNB).*

I. INTRODUCTION

Coronaviruses are a family of viruses that usually causes illness such as the common cold, severe acute respiratory syndrome (SARS). In March of 2019, a new coronavirus was identified as the cause of a pneumonia outbreak that originated in China. This Causative virus was initially termed as "Novel corona virus 2019" ,by WHO, later a coronavirus study group (CSG) Renamed the virus as "Severe acute respiratory syndrome corona virus 2" aka "SARS-CoV-2" and the it causes is called as "Corona virus disease 2019" aka "COVID-19". In March 2020, the World Health Organization (WHO) declared the COVID-19 outbreak a pandemic. The virus spreads by direct means such as droplet spread or by indirect means such as airborne spread. Due to longer incubation periods and contagiousness of the disease, the disease spreads rapidly in population cluster. Some patients can also be asymptomatic accelerating the spread of disease.

Elder population are usually at high risk of serious illness from COVID-19. The risk increases with age. There are certain medical conditions that increase risk of serious illness from Covid19, such as Heart disease, Cancer, Chronic obstructive pulmonary disease, Diabetes, Obesity, Hypertension, smoking, chronic kidney disease, weakened immune system, asthma, liver disease. On HRCT, Ground glass opacities are the areas of the increased lung opacity where underlying broncho vascular markings are not obscured. Ground glass opacity is usually the most common manifestation of Covid-19 pneumonia on HRCT chest imaging. Both lower lobes are the usually the most commonly involved. Often the common finding is multiple focal ground glass opacities in both lung fields. Reversed halo sign is also a typical finding visualized on HRCT. However there a few indeterminate findings noted are Diffuse ground glass opacities without any clear distribution, Nodular opacities with ground glass halo, focal consolidations and centrilobular nodules.

However, COVID-19 pneumonia sometimes, may manifest as unilateral Ground glass opacity, before the onset of symptoms with rapid progression into diffuse disease involving both lung fields. On 1 January 2021, the Drug Controller general of India (DCGI) approved emergency use of the Oxford-AstraZeneca

vaccine (local trade name "Covishield"). On 2 January, the DCGI also granted an interim emergency use authorization BBV152 (trade name "Covaxin"), a domestic vaccine developed by Bharat Biotech in association with the Indian Council of Medical research and National Institute of Virology. Both of them require 2 doses for complete vaccination with a interval 30 days in between both the doses.

The main objective of the study is to assess the severity of lung involvement in RT-PCR confirmed COVID-19 patients. And also to assess the severity of lung involvement to vaccination status, with either COVISHIELD or COVAXIN, and also with co-morbidities.

II. MATERIALS AND METHODS

This is a retrospective study done in the Department of Radiology and Imageology in a tertiary care center. The data is analyzed from 1st April 2021 to 30th April 2021, to identify patients (>16 years) who had confirmed (positive RT-PCR + SYMPTOMS) and underwent a HRCT Chest within 1st week (Avg <3.5 days) of RT-PCR Positive test (False positive rate 0.8-1.3%), to determine the extent of their lung involvement using the CT severity score (CT-SS).

All the patients (n=175) have undergone a standardized HRCT chest imaging protocol with single inspiratory breath hold. CT Images of the chest were obtained on a 16slice multidetector CT Unit (Philips Brilliance MRC 600) with 8—120 kVp, 20-40 mAs tube current, slice section of 1.5 mm, rotation 0.5, Matrix 512 x 512. Patients were classified in 3 groups based on their vaccination status to determine its correlation with the CT-SS score: fully vaccinated (received 2 doses of vaccine), partially vaccinated (one dose of vaccine), and unvaccinated.

All the cases were reviewed by two independent radiologist with 15 years and 2 years of experience and were blinded to the history. In all cases, semiquantitative CT severity scoring was calculated per each of the 5 lobes considering the extent of anatomic involvement, as follows: 0-No involvement; 1-< 5% involvement; 2- 5–25% involvement; 3- 26–50% involvement; 4- 51–75% involvement; and 5- > 75% involvement. The resulting CTSI score was the sum of each individual lobar score and (0 to 25). The CTSI scoring was classified into 3 groups (1)mild involvement with CTSI score 1-9 ;(2) moderate involvement with CTSI score 10-17;(3) severe involvement with CTSI score 18-25.

III. STATISTICAL ANALYSIS

Basic descriptive statistics were reported as frequencies and means. Student t test and ANOVA test were done and p value <0.05 was defined as statistically significant. The analysis was performed using Epi-info 7.1 software M.S.Windows.

IV. RESULTS & OBSERVATIONS

A total of n=175 patients were included in the study who have been confirmed cases of COVID -19 pneumonia by RT-PCR test and having symptoms. Almost 116 patients i.e 66.3% of the study population was Males& n=59 patients (33.7%) were females. Majority of the study population i.e, 45.7% was observed in the age group of 45-59 years when compared to other age groups. The Mean age of the study population was 49.03 years \pm 1.11.

Approximately 20% (n=34) of the study participants had taken 2 doses of COVID Vaccine (COVAXIN/COVISHIELD). Approximately 44.6% (n=78) of the study participants were not vaccinated.

The mean CTSI is higher in patients with co-morbidities compared to patients with no underlying condition. The mean CTSI in patients with Co-morbidities is 13.1 ± 4 , whereas in patients with no co-morbidities is 6 ± 3.2 .

The mean CTSI value of the study participants was 7.57 ± 0.5 .Majority (i.e 30 out of 35) of the study participants with no lung involvement were fully vaccinated which was statistically significant ($p < 0.001$). Majority of the study participants (i.e 30/34) who were completely vaccinated had no involvement of lung and only few had mild involvement of the lung. This observation is statistically highly significant ($p < 0.001$).

The CT severity score of the completely vaccinated patients was significantly lower (i.e., between 0 to 2), compared to partially vaccinated (i.e., between 2 to 18) & unvaccinated patients (i.e., between 2 to 23). The mean CT-SS of vaccinated, partially vaccinated & unvaccinated is 0.23 ± 0.11 , 6.98 ± 0.62 , & 11.46 ± 0.73 , respectively $p < 0.001$.

V. DISCUSSION

Approximately 20% (n=34) of the study participants had taken 2 doses of Covid Vaccine, which is higher than the India National average of 9.7% according to WHO. Approximately 44.6% (n=78)of the study participants was not vaccinated, which is less than the National average of 80.3% (according to WHO).The higher average vaccination status can be attributed to the fact that this is tertiary care center in a metro city where most of the population has access to the vaccine. The mean CTSI is higher in patients with co-morbidities compared to patients with ncondition. The mean CTSI in patients with Co-morbidities is 13.1 ± 4 , whereas in patients with no co-morbidities is 6 ± 3.2 . This observation is statistically significant ($p\text{-value} < 0.05$) and is consistent with previous studies.

The mean CTSI value of the study participants was 7.57 ± 0.5 . Most of the study population were having mild Lung Involvement based on CTSI. According to the study conducted by Marco et al, the

average CTSI in the population is 6.1 ± 1 with mild lung involvement, which is comparable to our study.

Majority (i.e 30 out of 35) of the study participants with no lung involvement were fully vaccinated which was statistically significant ($p < 0.001$) Majority of the study participants (i.e 30/34) who were completely vaccinated had no involvement of lung and only few had mild involvement of the lung. This observation is statistically highly significant ($p < 0.001$). Among the vaccinated patients, there was no significant difference in CTSI between COVISHIELD (mean CTSI 0.22 ± 0.8) and COVAXIN (mean CTSI 0.23 ± 0.3).

The CT severity score of the completely vaccinated patients was significantly lower (i.e., between 0 to 2), compared to partially vaccinated (i.e., between 2 to 18) & unvaccinated patients (i.e., between 2 to 23). The mean CT-SS of vaccinated, partially vaccinated & unvaccinated is 0.23 ± 0.11 , 6.98 ± 0.62 , & 11.46 ± 0.73 , respectively $p < 0.001$. This is comparable to the other similar studies done by Jaimin et al., University of Louisville School of Medicine. A multivariate linear regression model showed that partial or fully vaccinated patient's had lower CT severity score compared to vaccinated patients (adjusted R squared = 0.41).

Our study has few limitations. The study is done in a single tertiary care center, thus could have a selection bias affecting the generalizability of the study. Only 20% (40/175) of our study population is completely vaccinated. A study population with higher vaccination status compared to unvaccinated could give a better comparison and analysis

VI. CONCLUSION

CT severity score is higher in patients with Co-morbidities compared to patients with no underlying medical condition. CT severity score in fully vaccinated patients is significantly lower compared to partially vaccinated or unvaccinated patients. Complete vaccination could be critical in preventing severe lung disease. However, we found no significant difference in CT-SS of vaccinated patients who had taken either COVISHIELD or COVAXIN.

REFERENCES RÉFÉRENCES REFERENCIAS

1. Wasilewski, Piotr G et al. "COVID-19 severity scoring systems in radiological imaging - a review." Polish journal of radiology vol. 85 e361-e368. 17 Jul. 2020,
2. Coronavirus Disease 2019 (COVID-19): Role of Chest CT in Diagnosis and Management. American Journal of Roentgenology. 2020; 214: 1280-1286.
3. Zhang, J., Meng, G., Li, W. et al. Relationship of chest CT score with clinical characteristics of patients hospitalized with COVID-19 in Wuhan, China. Respir Res 21, 180(2020).
4. Epidemiological and clinical characteristics of 2019 novel coronavirus pneumonia in Wuhan, China: a

descriptive study. The Lancet, Elsevier. 15–21 February 2020

GLOBAL JOURNALS GUIDELINES HANDBOOK 2023

WWW.GLOBALJOURNALS.ORG

MEMBERSHIPS

FELLOWS/ASSOCIATES OF MEDICAL RESEARCH COUNCIL

FMRC/AMRC MEMBERSHIPS

INTRODUCTION



FMRC/AMRC is the most prestigious membership of Global Journals accredited by Open Association of Research Society, U.S.A (OARS). The credentials of Fellow and Associate designations signify that the researcher has gained the knowledge of the fundamental and high-level concepts, and is a subject matter expert, proficient in an expertise course covering the professional code of conduct, and follows recognized standards of practice. The credentials are designated only to the researchers, scientists, and professionals that have been selected by a rigorous process by our Editorial Board and Management Board.

Associates of FMRC/AMRC are scientists and researchers from around the world are working on projects/researches that have huge potentials. Members support Global Journals' mission to advance technology for humanity and the profession.

FMRC

FELLOW OF MEDICAL RESEARCH COUNCIL

FELLOW OF MEDICAL RESEARCH COUNCIL is the most prestigious membership of Global Journals. It is an award and membership granted to individuals that the Open Association of Research Society judges to have made a 'substantial contribution to the improvement of computer science, technology, and electronics engineering.

The primary objective is to recognize the leaders in research and scientific fields of the current era with a global perspective and to create a channel between them and other researchers for better exposure and knowledge sharing. Members are most eminent scientists, engineers, and technologists from all across the world. Fellows are elected for life through a peer review process on the basis of excellence in the respective domain. There is no limit on the number of new nominations made in any year. Each year, the Open Association of Research Society elect up to 12 new Fellow Members.



BENEFIT

TO THE INSTITUTION

GET LETTER OF APPRECIATION

Global Journals sends a letter of appreciation of author to the Dean or CEO of the University or Company of which author is a part, signed by editor in chief or chief author.



EXCLUSIVE NETWORK

GET ACCESS TO A CLOSED NETWORK

A FMRC member gets access to a closed network of Tier 1 researchers and scientists with direct communication channel through our website. Fellows can reach out to other members or researchers directly. They should also be open to reaching out by other.

Career

Credibility

Exclusive

Reputation



CERTIFICATE

CERTIFICATE, LOR AND LASER-MOMENTO

Fellows receive a printed copy of a certificate signed by our Chief Author that may be used for academic purposes and a personal recommendation letter to the dean of member's university.

Career

Credibility

Exclusive

Reputation



DESIGNATION

GET HONORED TITLE OF MEMBERSHIP

Fellows can use the honored title of membership. The "FMRC" is an honored title which is accorded to a person's name viz. Dr. John E. Hall, Ph.D., FMRC or William Walldroff, M.S., FMRC.

Career

Credibility

Exclusive

Reputation

RECOGNITION ON THE PLATFORM

BETTER VISIBILITY AND CITATION

All the Fellow members of FMRC get a badge of "Leading Member of Global Journals" on the Research Community that distinguishes them from others. Additionally, the profile is also partially maintained by our team for better visibility and citation. All fellows get a dedicated page on the website with their biography.

Career

Credibility

Reputation

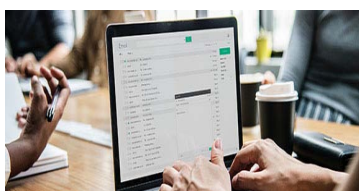FUTURE WORK

GET DISCOUNTS ON THE FUTURE PUBLICATIONS

Fellows receive discounts on the future publications with Global Journals up to 60%. Through our recommendation programs, members also receive discounts on publications made with OARS affiliated organizations.

Career

Financial



GJ INTERNAL ACCOUNT

UNLIMITED FORWARD OF EMAILS

Fellows get secure and fast GJ work emails with unlimited storage of emails that they may use them as their primary email. For example, john [AT] globaljournals [DOT] org.

Career

Credibility

Reputation



PREMIUM TOOLS

ACCESS TO ALL THE PREMIUM TOOLS

To take future researches to the zenith, fellows receive access to all the premium tools that Global Journals have to offer along with the partnership with some of the best marketing leading tools out there.

Financial

CONFERENCES & EVENTS

ORGANIZE SEMINAR/CONFERENCE

Fellows are authorized to organize symposium/seminar/conference on behalf of Global Journal Incorporation (USA). They can also participate in the same organized by another institution as representative of Global Journal. In both the cases, it is mandatory for him to discuss with us and obtain our consent. Additionally, they get free research conferences (and others) alerts.

Career

Credibility

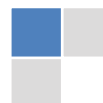Financial

EARLY INVITATIONS

EARLY INVITATIONS TO ALL THE SYMPOSIUMS, SEMINARS, CONFERENCES

All fellows receive the early invitations to all the symposiums, seminars, conferences and webinars hosted by Global Journals in their subject.

Exclusive





PUBLISHING ARTICLES & BOOKS

EARN 60% OF SALES PROCEEDS

Fellows can publish articles (limited) without any fees. Also, they can earn up to 70% of sales proceeds from the sale of reference/review books/literature/publishing of research paper. The FMRC member can decide its price and we can help in making the right decision.

Exclusive

Financial

REVIEWERS

GET A REMUNERATION OF 15% OF AUTHOR FEES

Fellow members are eligible to join as a paid peer reviewer at Global Journals Incorporation (USA) and can get a remuneration of 15% of author fees, taken from the author of a respective paper.

Financial

ACCESS TO EDITORIAL BOARD

BECOME A MEMBER OF THE EDITORIAL BOARD

Fellows and Associates may join as a member of the Editorial Board of Global Journals Incorporation (USA) after successful completion of three years as Fellow and as Peer Reviewer.

Career

Credibility

Exclusive

Reputation

AND MUCH MORE

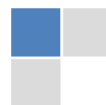GET ACCESS TO SCIENTIFIC MUSEUMS AND OBSERVATORIES ACROSS THE GLOBE

All members get access to 5 selected scientific museums and observatories across the globe. All researches published with Global Journals will be kept under deep archival facilities across regions for future protections and disaster recovery. They get 10 GB free secure cloud access for storing research files.

ASSOCIATE OF MEDICAL RESEARCH COUNCIL

ASSOCIATE OF MEDICAL RESEARCH COUNCIL is the membership of Global Journals awarded to individuals that the Open Association of Research Society judges to have made a 'substantial contribution to the improvement of computer science, technology, and electronics engineering.

The primary objective is to recognize the leaders in research and scientific fields of the current era with a global perspective and to create a channel between them and other researchers for better exposure and knowledge sharing. Members are most eminent scientists, engineers, and technologists from all across the world. Associate membership can later be promoted to Fellow Membership. Associates are elected for life through a peer review process on the basis of excellence in the respective domain. There is no limit on the number of new nominations made in any year. Each year, the Open Association of Research Society elect up to 12 new Associate Members.



BENEFIT

TO THE INSTITUTION

GET LETTER OF APPRECIATION

Global Journals sends a letter of appreciation of author to the Dean or CEO of the University or Company of which author is a part, signed by editor in chief or chief author.



EXCLUSIVE NETWORK

GET ACCESS TO A CLOSED NETWORK

A AMRC member gets access to a closed network of Tier 2 researchers and scientists with direct communication channel through our website. Associates can reach out to other members or researchers directly. They should also be open to reaching out by other.

Career

Credibility

Exclusive

Reputation



CERTIFICATE

CERTIFICATE, LOR AND LASER-MOMENTO

Associates receive a printed copy of a certificate signed by our Chief Author that may be used for academic purposes and a personal recommendation letter to the dean of member's university.

Career

Credibility

Exclusive

Reputation



DESIGNATION

GET HONORED TITLE OF MEMBERSHIP

Associates can use the honored title of membership. The "AMRC" is an honored title which is accorded to a person's name viz. Dr. John E. Hall, Ph.D., AMRC or William Walldroff, M.S., AMRC.

Career

Credibility

Exclusive

Reputation

RECOGNITION ON THE PLATFORM

BETTER VISIBILITY AND CITATION

All the Associate members of AMRC get a badge of "Leading Member of Global Journals" on the Research Community that distinguishes them from others. Additionally, the profile is also partially maintained by our team for better visibility and citation.

Career

Credibility

Reputation

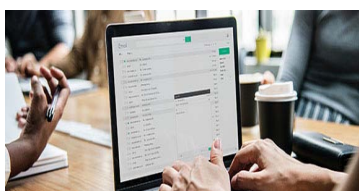FUTURE WORK

GET DISCOUNTS ON THE FUTURE PUBLICATIONS

Associates receive discounts on future publications with Global Journals up to 30%. Through our recommendation programs, members also receive discounts on publications made with OARS affiliated organizations.

Career

Financial



GJ ACCOUNT

UNLIMITED FORWARD OF EMAILS

Associates get secure and fast GJ work emails with 5GB forward of emails that they may use them as their primary email. For example, john [AT] globaljournals [DOT] org.

Career

Credibility

Reputation



PREMIUM TOOLS

ACCESS TO ALL THE PREMIUM TOOLS

To take future researches to the zenith, fellows receive access to almost all the premium tools that Global Journals have to offer along with the partnership with some of the best marketing leading tools out there.

Financial

CONFERENCES & EVENTS

ORGANIZE SEMINAR/CONFERENCE

Associates are authorized to organize symposium/seminar/conference on behalf of Global Journal Incorporation (USA). They can also participate in the same organized by another institution as representative of Global Journal. In both the cases, it is mandatory for him to discuss with us and obtain our consent. Additionally, they get free research conferences (and others) alerts.

Career

Credibility

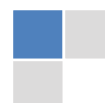Financial

EARLY INVITATIONS

EARLY INVITATIONS TO ALL THE SYMPOSIUMS, SEMINARS, CONFERENCES

All associates receive the early invitations to all the symposiums, seminars, conferences and webinars hosted by Global Journals in their subject.

Exclusive





PUBLISHING ARTICLES & BOOKS

EARN 60% OF SALES PROCEEDS

Associates can publish articles (limited) without any fees. Also, they can earn up to 30-40% of sales proceeds from the sale of reference/review books/literature/publishing of research paper

Exclusive

Financial

REVIEWERS

GET A REMUNERATION OF 15% OF AUTHOR FEES

Associate members are eligible to join as a paid peer reviewer at Global Journals Incorporation (USA) and can get a remuneration of 15% of author fees, taken from the author of a respective paper.


Financial

AND MUCH MORE

GET ACCESS TO SCIENTIFIC MUSEUMS AND OBSERVATORIES ACROSS THE GLOBE

All members get access to 2 selected scientific museums and observatories across the globe. All researches published with Global Journals will be kept under deep archival facilities across regions for future protections and disaster recovery. They get 5 GB free secure cloud access for storing research files.





ASSOCIATE	FELLOW	RESEARCH GROUP	BASIC
<p>\$4800 lifetime designation</p> <hr/> <p>Certificate, LoR and Momento 2 discounted publishing/year Gradation of Research 10 research contacts/day 1 GB Cloud Storage GJ Community Access</p>	<p>\$6800 lifetime designation</p> <hr/> <p>Certificate, LoR and Momento Unlimited discounted publishing/year Gradation of Research Unlimited research contacts/day 5 GB Cloud Storage Online Presense Assistance GJ Community Access</p>	<p>\$12500.00 organizational</p> <hr/> <p>Certificates, LoRs and Momentos Unlimited free publishing/year Gradation of Research Unlimited research contacts/day Unlimited Cloud Storage Online Presense Assistance GJ Community Access</p>	<p>APC per article</p> <hr/> <p>GJ Community Access</p>



PREFERRED AUTHOR GUIDELINES

We accept the manuscript submissions in any standard (generic) format.

We typeset manuscripts using advanced typesetting tools like Adobe In Design, CorelDraw, TeXnicCenter, and TeXStudio. We usually recommend authors submit their research using any standard format they are comfortable with, and let Global Journals do the rest.

Alternatively, you can download our basic template from <https://globaljournals.org/Template>

Authors should submit their complete paper/article, including text illustrations, graphics, conclusions, artwork, and tables. Authors who are not able to submit manuscript using the form above can email the manuscript department at submit@globaljournals.org or get in touch with chiefeditor@globaljournals.org if they wish to send the abstract before submission.

BEFORE AND DURING SUBMISSION

Authors must ensure the information provided during the submission of a paper is authentic. Please go through the following checklist before submitting:

1. Authors must go through the complete author guideline and understand and *agree to Global Journals' ethics and code of conduct*, along with author responsibilities.
2. Authors must accept the privacy policy, terms, and conditions of Global Journals.
3. Ensure corresponding author's email address and postal address are accurate and reachable.
4. Manuscript to be submitted must include keywords, an abstract, a paper title, co-author(s') names and details (email address, name, phone number, and institution), figures and illustrations in vector format including appropriate captions, tables, including titles and footnotes, a conclusion, results, acknowledgments and references.
5. Authors should submit paper in a ZIP archive if any supplementary files are required along with the paper.
6. Proper permissions must be acquired for the use of any copyrighted material.
7. Manuscript submitted *must not have been submitted or published elsewhere* and all authors must be aware of the submission.

Declaration of Conflicts of Interest

It is required for authors to declare all financial, institutional, and personal relationships with other individuals and organizations that could influence (bias) their research.

POLICY ON PLAGIARISM

Plagiarism is not acceptable in Global Journals submissions at all.

Plagiarized content will not be considered for publication. We reserve the right to inform authors' institutions about plagiarism detected either before or after publication. If plagiarism is identified, we will follow COPE guidelines:

Authors are solely responsible for all the plagiarism that is found. The author must not fabricate, falsify or plagiarize existing research data. The following, if copied, will be considered plagiarism:

- Words (language)
- Ideas
- Findings
- Writings
- Diagrams
- Graphs
- Illustrations
- Lectures



- Printed material
- Graphic representations
- Computer programs
- Electronic material
- Any other original work

AUTHORSHIP POLICIES

Global Journals follows the definition of authorship set up by the Open Association of Research Society, USA. According to its guidelines, authorship criteria must be based on:

1. Substantial contributions to the conception and acquisition of data, analysis, and interpretation of findings.
2. Drafting the paper and revising it critically regarding important academic content.
3. Final approval of the version of the paper to be published.

Changes in Authorship

The corresponding author should mention the name and complete details of all co-authors during submission and in manuscript. We support addition, rearrangement, manipulation, and deletions in authors list till the early view publication of the journal. We expect that corresponding author will notify all co-authors of submission. We follow COPE guidelines for changes in authorship.

Copyright

During submission of the manuscript, the author is confirming an exclusive license agreement with Global Journals which gives Global Journals the authority to reproduce, reuse, and republish authors' research. We also believe in flexible copyright terms where copyright may remain with authors/employers/institutions as well. Contact your editor after acceptance to choose your copyright policy. You may follow this form for copyright transfers.

Appealing Decisions

Unless specified in the notification, the Editorial Board's decision on publication of the paper is final and cannot be appealed before making the major change in the manuscript.

Acknowledgments

Contributors to the research other than authors credited should be mentioned in Acknowledgments. The source of funding for the research can be included. Suppliers of resources may be mentioned along with their addresses.

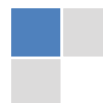Declaration of funding sources

Global Journals is in partnership with various universities, laboratories, and other institutions worldwide in the research domain. Authors are requested to disclose their source of funding during every stage of their research, such as making analysis, performing laboratory operations, computing data, and using institutional resources, from writing an article to its submission. This will also help authors to get reimbursements by requesting an open access publication letter from Global Journals and submitting to the respective funding source.

PREPARING YOUR MANUSCRIPT

Authors can submit papers and articles in an acceptable file format: MS Word (doc, docx), LaTeX (.tex, .zip or .rar including all of your files), Adobe PDF (.pdf), rich text format (.rtf), simple text document (.txt), Open Document Text (.odt), and Apple Pages (.pages). Our professional layout editors will format the entire paper according to our official guidelines. This is one of the highlights of publishing with Global Journals—authors should not be concerned about the formatting of their paper. Global Journals accepts articles and manuscripts in every major language, be it Spanish, Chinese, Japanese, Portuguese, Russian, French, German, Dutch, Italian, Greek, or any other national language, but the title, subtitle, and abstract should be in English. This will facilitate indexing and the pre-peer review process.

The following is the official style and template developed for publication of a research paper. Authors are not required to follow this style during the submission of the paper. It is just for reference purposes.



Manuscript Style Instruction (Optional)

- Microsoft Word Document Setting Instructions.
- Font type of all text should be Swis721 Lt BT.
- Page size: 8.27" x 11", left margin: 0.65, right margin: 0.65, bottom margin: 0.75.
- Paper title should be in one column of font size 24.
- Author name in font size of 11 in one column.
- Abstract: font size 9 with the word "Abstract" in bold italics.
- Main text: font size 10 with two justified columns.
- Two columns with equal column width of 3.38 and spacing of 0.2.
- First character must be three lines drop-capped.
- The paragraph before spacing of 1 pt and after of 0 pt.
- Line spacing of 1 pt.
- Large images must be in one column.
- The names of first main headings (Heading 1) must be in Roman font, capital letters, and font size of 10.
- The names of second main headings (Heading 2) must not include numbers and must be in italics with a font size of 10.

Structure and Format of Manuscript

The recommended size of an original research paper is under 15,000 words and review papers under 7,000 words. Research articles should be less than 10,000 words. Research papers are usually longer than review papers. Review papers are reports of significant research (typically less than 7,000 words, including tables, figures, and references)

A research paper must include:

- a) A title which should be relevant to the theme of the paper.
- b) A summary, known as an abstract (less than 150 words), containing the major results and conclusions.
- c) Up to 10 keywords that precisely identify the paper's subject, purpose, and focus.
- d) An introduction, giving fundamental background objectives.
- e) Resources and techniques with sufficient complete experimental details (wherever possible by reference) to permit repetition, sources of information must be given, and numerical methods must be specified by reference.
- f) Results which should be presented concisely by well-designed tables and figures.
- g) Suitable statistical data should also be given.
- h) All data must have been gathered with attention to numerical detail in the planning stage.

Design has been recognized to be essential to experiments for a considerable time, and the editor has decided that any paper that appears not to have adequate numerical treatments of the data will be returned unrefereed.

- i) Discussion should cover implications and consequences and not just recapitulate the results; conclusions should also be summarized.
- j) There should be brief acknowledgments.
- k) There ought to be references in the conventional format. Global Journals recommends APA format.

Authors should carefully consider the preparation of papers to ensure that they communicate effectively. Papers are much more likely to be accepted if they are carefully designed and laid out, contain few or no errors, are summarizing, and follow instructions. They will also be published with much fewer delays than those that require much technical and editorial correction.

The Editorial Board reserves the right to make literary corrections and suggestions to improve brevity.

FORMAT STRUCTURE

It is necessary that authors take care in submitting a manuscript that is written in simple language and adheres to published guidelines.

All manuscripts submitted to Global Journals should include:

Title

The title page must carry an informative title that reflects the content, a running title (less than 45 characters together with spaces), names of the authors and co-authors, and the place(s) where the work was carried out.

Author details

The full postal address of any related author(s) must be specified.

Abstract

The abstract is the foundation of the research paper. It should be clear and concise and must contain the objective of the paper and inferences drawn. It is advised to not include big mathematical equations or complicated jargon.

Many researchers searching for information online will use search engines such as Google, Yahoo or others. By optimizing your paper for search engines, you will amplify the chance of someone finding it. In turn, this will make it more likely to be viewed and cited in further works. Global Journals has compiled these guidelines to facilitate you to maximize the web-friendliness of the most public part of your paper.

Keywords

A major lynchpin of research work for the writing of research papers is the keyword search, which one will employ to find both library and internet resources. Up to eleven keywords or very brief phrases have to be given to help data retrieval, mining, and indexing.

One must be persistent and creative in using keywords. An effective keyword search requires a strategy: planning of a list of possible keywords and phrases to try.

Choice of the main keywords is the first tool of writing a research paper. Research paper writing is an art. Keyword search should be as strategic as possible.

One should start brainstorming lists of potential keywords before even beginning searching. Think about the most important concepts related to research work. Ask, "What words would a source have to include to be truly valuable in a research paper?" Then consider synonyms for the important words.

It may take the discovery of only one important paper to steer in the right keyword direction because, in most databases, the keywords under which a research paper is abstracted are listed with the paper.

Numerical Methods

Numerical methods used should be transparent and, where appropriate, supported by references.

Abbreviations

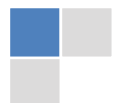Authors must list all the abbreviations used in the paper at the end of the paper or in a separate table before using them.

Formulas and equations

Authors are advised to submit any mathematical equation using either MathJax, KaTeX, or LaTeX, or in a very high-quality image.

Tables, Figures, and Figure Legends

Tables: Tables should be cautiously designed, uncrowned, and include only essential data. Each must have an Arabic number, e.g., Table 4, a self-explanatory caption, and be on a separate sheet. Authors must submit tables in an editable format and not as images. References to these tables (if any) must be mentioned accurately.



Figures

Figures are supposed to be submitted as separate files. Always include a citation in the text for each figure using Arabic numbers, e.g., Fig. 4. Artwork must be submitted online in vector electronic form or by emailing it.

PREPARATION OF ELETRONIC FIGURES FOR PUBLICATION

Although low-quality images are sufficient for review purposes, print publication requires high-quality images to prevent the final product being blurred or fuzzy. Submit (possibly by e-mail) EPS (line art) or TIFF (halftone/ photographs) files only. MS PowerPoint and Word Graphics are unsuitable for printed pictures. Avoid using pixel-oriented software. Scans (TIFF only) should have a resolution of at least 350 dpi (halftone) or 700 to 1100 dpi (line drawings). Please give the data for figures in black and white or submit a Color Work Agreement form. EPS files must be saved with fonts embedded (and with a TIFF preview, if possible).

For scanned images, the scanning resolution at final image size ought to be as follows to ensure good reproduction: line art: >650 dpi; halftones (including gel photographs): >350 dpi; figures containing both halftone and line images: >650 dpi.

Color charges: Authors are advised to pay the full cost for the reproduction of their color artwork. Hence, please note that if there is color artwork in your manuscript when it is accepted for publication, we would require you to complete and return a Color Work Agreement form before your paper can be published. Also, you can email your editor to remove the color fee after acceptance of the paper.

TIPS FOR WRITING A GOOD QUALITY MEDICAL RESEARCH PAPER

1. Choosing the topic: In most cases, the topic is selected by the interests of the author, but it can also be suggested by the guides. You can have several topics, and then judge which you are most comfortable with. This may be done by asking several questions of yourself, like "Will I be able to carry out a search in this area? Will I find all necessary resources to accomplish the search? Will I be able to find all information in this field area?" If the answer to this type of question is "yes," then you ought to choose that topic. In most cases, you may have to conduct surveys and visit several places. Also, you might have to do a lot of work to find all the rises and falls of the various data on that subject. Sometimes, detailed information plays a vital role, instead of short information. Evaluators are human: The first thing to remember is that evaluators are also human beings. They are not only meant for rejecting a paper. They are here to evaluate your paper. So present your best aspect.

2. Think like evaluators: If you are in confusion or getting demotivated because your paper may not be accepted by the evaluators, then think, and try to evaluate your paper like an evaluator. Try to understand what an evaluator wants in your research paper, and you will automatically have your answer. Make blueprints of paper: The outline is the plan or framework that will help you to arrange your thoughts. It will make your paper logical. But remember that all points of your outline must be related to the topic you have chosen.

3. Ask your guides: If you are having any difficulty with your research, then do not hesitate to share your difficulty with your guide (if you have one). They will surely help you out and resolve your doubts. If you can't clarify what exactly you require for your work, then ask your supervisor to help you with an alternative. He or she might also provide you with a list of essential readings.

4. Use of computer is recommended: As you are doing research in the field of medical research then this point is quite obvious. Use right software: Always use good quality software packages. If you are not capable of judging good software, then you can lose the quality of your paper unknowingly. There are various programs available to help you which you can get through the internet.

5. Use the internet for help: An excellent start for your paper is using Google. It is a wondrous search engine, where you can have your doubts resolved. You may also read some answers for the frequent question of how to write your research paper or find a model research paper. You can download books from the internet. If you have all the required books, place importance on reading, selecting, and analyzing the specified information. Then sketch out your research paper. Use big pictures: You may use encyclopedias like Wikipedia to get pictures with the best resolution. At Global Journals, you should strictly follow here.



6. Bookmarks are useful: When you read any book or magazine, you generally use bookmarks, right? It is a good habit which helps to not lose your continuity. You should always use bookmarks while searching on the internet also, which will make your search easier.

7. Revise what you wrote: When you write anything, always read it, summarize it, and then finalize it.

8. Make every effort: Make every effort to mention what you are going to write in your paper. That means always have a good start. Try to mention everything in the introduction—what is the need for a particular research paper. Polish your work with good writing skills and always give an evaluator what he wants. Make backups: When you are going to do any important thing like making a research paper, you should always have backup copies of it either on your computer or on paper. This protects you from losing any portion of your important data.

9. Produce good diagrams of your own: Always try to include good charts or diagrams in your paper to improve quality. Using several unnecessary diagrams will degrade the quality of your paper by creating a hodgepodge. So always try to include diagrams which were made by you to improve the readability of your paper. Use of direct quotes: When you do research relevant to literature, history, or current affairs, then use of quotes becomes essential, but if the study is relevant to science, use of quotes is not preferable.

10. Use proper verb tense: Use proper verb tenses in your paper. Use past tense to present those events that have happened. Use present tense to indicate events that are going on. Use future tense to indicate events that will happen in the future. Use of wrong tenses will confuse the evaluator. Avoid sentences that are incomplete.

11. Pick a good study spot: Always try to pick a spot for your research which is quiet. Not every spot is good for studying.

12. Know what you know: Always try to know what you know by making objectives, otherwise you will be confused and unable to achieve your target.

13. Use good grammar: Always use good grammar and words that will have a positive impact on the evaluator; use of good vocabulary does not mean using tough words which the evaluator has to find in a dictionary. Do not fragment sentences. Eliminate one-word sentences. Do not ever use a big word when a smaller one would suffice.

Verbs have to be in agreement with their subjects. In a research paper, do not start sentences with conjunctions or finish them with prepositions. When writing formally, it is advisable to never split an infinitive because someone will (wrongly) complain. Avoid clichés like a disease. Always shun irritating alliteration. Use language which is simple and straightforward. Put together a neat summary.

14. Arrangement of information: Each section of the main body should start with an opening sentence, and there should be a changeover at the end of the section. Give only valid and powerful arguments for your topic. You may also maintain your arguments with records.

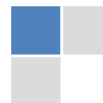15. Never start at the last minute: Always allow enough time for research work. Leaving everything to the last minute will degrade your paper and spoil your work.

16. Multitasking in research is not good: Doing several things at the same time is a bad habit in the case of research activity. Research is an area where everything has a particular time slot. Divide your research work into parts, and do a particular part in a particular time slot.

17. Never copy others' work: Never copy others' work and give it your name because if the evaluator has seen it anywhere, you will be in trouble. Take proper rest and food: No matter how many hours you spend on your research activity, if you are not taking care of your health, then all your efforts will have been in vain. For quality research, take proper rest and food.

18. Go to seminars: Attend seminars if the topic is relevant to your research area. Utilize all your resources.

19. Refresh your mind after intervals: Try to give your mind a rest by listening to soft music or sleeping in intervals. This will also improve your memory. Acquire colleagues: Always try to acquire colleagues. No matter how sharp you are, if you acquire colleagues, they can give you ideas which will be helpful to your research.



20. Think technically: Always think technically. If anything happens, search for its reasons, benefits, and demerits. Think and then print: When you go to print your paper, check that tables are not split, headings are not detached from their descriptions, and page sequence is maintained.

21. Adding unnecessary information: Do not add unnecessary information like "I have used MS Excel to draw graphs." Irrelevant and inappropriate material is superfluous. Foreign terminology and phrases are not apropos. One should never take a broad view. Analogy is like feathers on a snake. Use words properly, regardless of how others use them. Remove quotations. Puns are for kids, not grunt readers. Never oversimplify: When adding material to your research paper, never go for oversimplification; this will definitely irritate the evaluator. Be specific. Never use rhythmic redundancies. Contractions shouldn't be used in a research paper. Comparisons are as terrible as clichés. Give up ampersands, abbreviations, and so on. Remove commas that are not necessary. Parenthetical words should be between brackets or commas. Understatement is always the best way to put forward earth-shaking thoughts. Give a detailed literary review.

22. Report concluded results: Use concluded results. From raw data, filter the results, and then conclude your studies based on measurements and observations taken. An appropriate number of decimal places should be used. Parenthetical remarks are prohibited here. Proofread carefully at the final stage. At the end, give an outline to your arguments. Spot perspectives of further study of the subject. Justify your conclusion at the bottom sufficiently, which will probably include examples.

23. Upon conclusion: Once you have concluded your research, the next most important step is to present your findings. Presentation is extremely important as it is the definite medium through which your research is going to be in print for the rest of the crowd. Care should be taken to categorize your thoughts well and present them in a logical and neat manner. A good quality research paper format is essential because it serves to highlight your research paper and bring to light all necessary aspects of your research.

INFORMAL GUIDELINES OF RESEARCH PAPER WRITING

Key points to remember:

- Submit all work in its final form.
- Write your paper in the form which is presented in the guidelines using the template.
- Please note the criteria peer reviewers will use for grading the final paper.

Final points:

One purpose of organizing a research paper is to let people interpret your efforts selectively. The journal requires the following sections, submitted in the order listed, with each section starting on a new page:

The introduction: This will be compiled from reference matter and reflect the design processes or outline of basis that directed you to make a study. As you carry out the process of study, the method and process section will be constructed like that. The results segment will show related statistics in nearly sequential order and direct reviewers to similar intellectual paths throughout the data that you gathered to carry out your study.

The discussion section:

This will provide understanding of the data and projections as to the implications of the results. The use of good quality references throughout the paper will give the effort trustworthiness by representing an alertness to prior workings.

Writing a research paper is not an easy job, no matter how trouble-free the actual research or concept. Practice, excellent preparation, and controlled record-keeping are the only means to make straightforward progression.

General style:

Specific editorial column necessities for compliance of a manuscript will always take over from directions in these general guidelines.

To make a paper clear: Adhere to recommended page limits.



Mistakes to avoid:

- Insertion of a title at the foot of a page with subsequent text on the next page.
- Separating a table, chart, or figure—confine each to a single page.
- Submitting a manuscript with pages out of sequence.
- In every section of your document, use standard writing style, including articles ("a" and "the").
- Keep paying attention to the topic of the paper.
- Use paragraphs to split each significant point (excluding the abstract).
- Align the primary line of each section.
- Present your points in sound order.
- Use present tense to report well-accepted matters.
- Use past tense to describe specific results.
- Do not use familiar wording; don't address the reviewer directly. Don't use slang or superlatives.
- Avoid use of extra pictures—include only those figures essential to presenting results.

Title page:

Choose a revealing title. It should be short and include the name(s) and address(es) of all authors. It should not have acronyms or abbreviations or exceed two printed lines.

Abstract: This summary should be two hundred words or less. It should clearly and briefly explain the key findings reported in the manuscript and must have precise statistics. It should not have acronyms or abbreviations. It should be logical in itself. Do not cite references at this point.

An abstract is a brief, distinct paragraph summary of finished work or work in development. In a minute or less, a reviewer can be taught the foundation behind the study, common approaches to the problem, relevant results, and significant conclusions or new questions.

Write your summary when your paper is completed because how can you write the summary of anything which is not yet written? Wealth of terminology is very essential in abstract. Use comprehensive sentences, and do not sacrifice readability for brevity; you can maintain it succinctly by phrasing sentences so that they provide more than a lone rationale. The author can at this moment go straight to shortening the outcome. Sum up the study with the subsequent elements in any summary. Try to limit the initial two items to no more than one line each.

Reason for writing the article—theory, overall issue, purpose.

- Fundamental goal.
- To-the-point depiction of the research.
- Consequences, including definite statistics—if the consequences are quantitative in nature, account for this; results of any numerical analysis should be reported. Significant conclusions or questions that emerge from the research.

Approach:

- Single section and succinct.
- An outline of the job done is always written in past tense.
- Concentrate on shortening results—limit background information to a verdict or two.
- Exact spelling, clarity of sentences and phrases, and appropriate reporting of quantities (proper units, important statistics) are just as significant in an abstract as they are anywhere else.

Introduction:

The introduction should "introduce" the manuscript. The reviewer should be presented with sufficient background information to be capable of comprehending and calculating the purpose of your study without having to refer to other works. The basis for the study should be offered. Give the most important references, but avoid making a comprehensive appraisal of the topic. Describe the problem visibly. If the problem is not acknowledged in a logical, reasonable way, the reviewer will give no attention to your results. Speak in common terms about techniques used to explain the problem, if needed, but do not present any particulars about the protocols here.



The following approach can create a valuable beginning:

- Explain the value (significance) of the study.
- Defend the model—why did you employ this particular system or method? What is its compensation? Remark upon its appropriateness from an abstract point of view as well as pointing out sensible reasons for using it.
- Present a justification. State your particular theory(-ies) or aim(s), and describe the logic that led you to choose them.
- Briefly explain the study's tentative purpose and how it meets the declared objectives.

Approach:

Use past tense except for when referring to recognized facts. After all, the manuscript will be submitted after the entire job is done. Sort out your thoughts; manufacture one key point for every section. If you make the four points listed above, you will need at least four paragraphs. Present surrounding information only when it is necessary to support a situation. The reviewer does not desire to read everything you know about a topic. Shape the theory specifically—do not take a broad view.

As always, give awareness to spelling, simplicity, and correctness of sentences and phrases.

Procedures (methods and materials):

This part is supposed to be the easiest to carve if you have good skills. A soundly written procedures segment allows a capable scientist to replicate your results. Present precise information about your supplies. The suppliers and clarity of reagents can be helpful bits of information. Present methods in sequential order, but linked methodologies can be grouped as a segment. Be concise when relating the protocols. Attempt to give the least amount of information that would permit another capable scientist to replicate your outcome, but be cautious that vital information is integrated. The use of subheadings is suggested and ought to be synchronized with the results section.

When a technique is used that has been well-described in another section, mention the specific item describing the way, but draw the basic principle while stating the situation. The purpose is to show all particular resources and broad procedures so that another person may use some or all of the methods in one more study or referee the scientific value of your work. It is not to be a step-by-step report of the whole thing you did, nor is a methods section a set of orders.

Materials:

Materials may be reported in part of a section or else they may be recognized along with your measures.

Methods:

- Report the method and not the particulars of each process that engaged the same methodology.
- Describe the method entirely.
- To be succinct, present methods under headings dedicated to specific dealings or groups of measures.
- Simplify—detail how procedures were completed, not how they were performed on a particular day.
- If well-known procedures were used, account for the procedure by name, possibly with a reference, and that's all.

Approach:

It is embarrassing to use vigorous voice when documenting methods without using first person, which would focus the reviewer's interest on the researcher rather than the job. As a result, when writing up the methods, most authors use third person passive voice.

Use standard style in this and every other part of the paper—avoid familiar lists, and use full sentences.

What to keep away from:

- Resources and methods are not a set of information.
- Skip all descriptive information and surroundings—save it for the argument.
- Leave out information that is immaterial to a third party.



Results:

The principle of a results segment is to present and demonstrate your conclusion. Create this part as entirely objective details of the outcome, and save all understanding for the discussion.

The page length of this segment is set by the sum and types of data to be reported. Use statistics and tables, if suitable, to present consequences most efficiently.

You must clearly differentiate material which would usually be incorporated in a study editorial from any unprocessed data or additional appendix matter that would not be available. In fact, such matters should not be submitted at all except if requested by the instructor.

Content:

- Sum up your conclusions in text and demonstrate them, if suitable, with figures and tables.
- In the manuscript, explain each of your consequences, and point the reader to remarks that are most appropriate.
- Present a background, such as by describing the question that was addressed by creation of an exacting study.
- Explain results of control experiments and give remarks that are not accessible in a prescribed figure or table, if appropriate.
- Examine your data, then prepare the analyzed (transformed) data in the form of a figure (graph), table, or manuscript.

What to stay away from:

- Do not discuss or infer your outcome, report surrounding information, or try to explain anything.
- Do not include raw data or intermediate calculations in a research manuscript.
- Do not present similar data more than once.
- A manuscript should complement any figures or tables, not duplicate information.
- Never confuse figures with tables—there is a difference.

Approach:

As always, use past tense when you submit your results, and put the whole thing in a reasonable order.

Put figures and tables, appropriately numbered, in order at the end of the report.

If you desire, you may place your figures and tables properly within the text of your results section.

Figures and tables:

If you put figures and tables at the end of some details, make certain that they are visibly distinguished from any attached appendix materials, such as raw facts. Whatever the position, each table must be titled, numbered one after the other, and include a heading. All figures and tables must be divided from the text.

Discussion:

The discussion is expected to be the trickiest segment to write. A lot of papers submitted to the journal are discarded based on problems with the discussion. There is no rule for how long an argument should be.

Position your understanding of the outcome visibly to lead the reviewer through your conclusions, and then finish the paper with a summing up of the implications of the study. The purpose here is to offer an understanding of your results and support all of your conclusions, using facts from your research and generally accepted information, if suitable. The implication of results should be fully described.

Infer your data in the conversation in suitable depth. This means that when you clarify an observable fact, you must explain mechanisms that may account for the observation. If your results vary from your prospect, make clear why that may have happened. If your results agree, then explain the theory that the proof supported. It is never suitable to just state that the data approved the prospect, and let it drop at that. Make a decision as to whether each premise is supported or discarded or if you cannot make a conclusion with assurance. Do not just dismiss a study or part of a study as "uncertain."



Research papers are not acknowledged if the work is imperfect. Draw what conclusions you can based upon the results that you have, and take care of the study as a finished work.

- You may propose future guidelines, such as how an experiment might be personalized to accomplish a new idea.
- Give details of all of your remarks as much as possible, focusing on mechanisms.
- Make a decision as to whether the tentative design sufficiently addressed the theory and whether or not it was correctly restricted. Try to present substitute explanations if they are sensible alternatives.
- One piece of research will not counter an overall question, so maintain the large picture in mind. Where do you go next? The best studies unlock new avenues of study. What questions remain?
- Recommendations for detailed papers will offer supplementary suggestions.

Approach:

When you refer to information, differentiate data generated by your own studies from other available information. Present work done by specific persons (including you) in past tense.

Describe generally acknowledged facts and main beliefs in present tense.

THE ADMINISTRATION RULES

Administration Rules to Be Strictly Followed before Submitting Your Research Paper to Global Journals Inc.

Please read the following rules and regulations carefully before submitting your research paper to Global Journals Inc. to avoid rejection.

Segment draft and final research paper: You have to strictly follow the template of a research paper, failing which your paper may get rejected. You are expected to write each part of the paper wholly on your own. The peer reviewers need to identify your own perspective of the concepts in your own terms. Please do not extract straight from any other source, and do not rephrase someone else's analysis. Do not allow anyone else to proofread your manuscript.

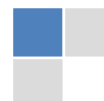Written material: You may discuss this with your guides and key sources. Do not copy anyone else's paper, even if this is only imitation, otherwise it will be rejected on the grounds of plagiarism, which is illegal. Various methods to avoid plagiarism are strictly applied by us to every paper, and, if found guilty, you may be blacklisted, which could affect your career adversely. To guard yourself and others from possible illegal use, please do not permit anyone to use or even read your paper and file.



CRITERION FOR GRADING A RESEARCH PAPER (COMPILATION)
BY GLOBAL JOURNALS

Please note that following table is only a Grading of "Paper Compilation" and not on "Performed/Stated Research" whose grading solely depends on Individual Assigned Peer Reviewer and Editorial Board Member. These can be available only on request and after decision of Paper. This report will be the property of Global Journals.

Topics	Grades		
	A-B	C-D	E-F
<i>Abstract</i>	Clear and concise with appropriate content, Correct format. 200 words or below	Unclear summary and no specific data, Incorrect form Above 200 words	No specific data with ambiguous information Above 250 words
<i>Introduction</i>	Containing all background details with clear goal and appropriate details, flow specification, no grammar and spelling mistake, well organized sentence and paragraph, reference cited	Unclear and confusing data, appropriate format, grammar and spelling errors with unorganized matter	Out of place depth and content, hazy format
<i>Methods and Procedures</i>	Clear and to the point with well arranged paragraph, precision and accuracy of facts and figures, well organized subheads	Difficult to comprehend with embarrassed text, too much explanation but completed	Incorrect and unorganized structure with hazy meaning
<i>Result</i>	Well organized, Clear and specific, Correct units with precision, correct data, well structuring of paragraph, no grammar and spelling mistake	Complete and embarrassed text, difficult to comprehend	Irregular format with wrong facts and figures
<i>Discussion</i>	Well organized, meaningful specification, sound conclusion, logical and concise explanation, highly structured paragraph reference cited	Wordy, unclear conclusion, spurious	Conclusion is not cited, unorganized, difficult to comprehend
<i>References</i>	Complete and correct format, well organized	Beside the point, Incomplete	Wrong format and structuring



INDEX

A

Acoustic · 20, 23, 24, 26
Adhesion · 25
Anticipate · 25

B

Boulevard · 4

E

Edematous · 20

I

Impregnation · 6, 14

P

Pertinent · 34

R

Resection · 2, 4, 6, 7

S

Sentinel · 16
Speculate · 25
Spiculated · 20, 23, 26, 29

U

Unveiled · 20



save our planet



Global Journal of Medical Research

Visit us on the Web at www.GlobalJournals.org | www.MedicalResearchJournal.org
or email us at helpdesk@globaljournals.org

ISSN 9755896



© Global Journals